

Prospective Evaluation of Results of Surgical Treatment of Patients with Idiopathic Macular Hole by Phacovitrectomy and Combined Cataract and Vitrectomy Surgery

Kinga Tochman-Kanty, Monika Jasielska, Jerzy Mackiewicz

Department of Retina and Vitreous Surgery, Medical University of Lublin, Poland
Head: Professor Jerzy Mackiewicz, MD, PhD

Abstract:

Purpose of the study: The purpose of the study was to compare the morphological and functional results of the studied patients with idiopathic macular hole treated with a one-stage method (phacovitrectomy) and combined cataract and vitrectomy surgery.

Material and methods: The study included 33 patients (33 eyes) with idiopathic macular hole treated at the Department of Retina and Vitreous Surgery in Lublin. Twenty-one eyes were surgically treated with phacovitrectomy (Group 1 MH). Twelve patients underwent two-stage, combined treatment with removal of the lens in the first stage and vitrectomy in the second (Group 2 MH). The assignment of patients to groups was random. All patients underwent 23-gauge sutureless vitrectomy with removal of the internal limiting membrane (internal limiting membrane peeling). SF₆ gas was used as an intraocular tamponade at an isovolumetric concentration of 20% and face down position recommendation for 7 days. Cataract surgery was performed using the phacoemulsification method with an incision in the transparent part of the cornea with intracapsular, posterior chamber implantation of a monofocal lens. A 12-month observation period was established, measured from the date of vitrectomy performance, and in the case of a combined procedure, this period was extended by the time between each stage of treatment. At subsequent check-ups, the subjects underwent a complete ophthalmological examination, which included: best corrected distance visual acuity and best corrected near visual acuity, assessment of the anterior and posterior segments, in a slit lamp, measurement of retinal sensitivity in the macula using microperimetry, the Amsler test and optical coherence tomography examination of the macula.

Results: In patients of the total studied group, an improvement in the best-corrected visual distance and near acuity was obtained, and in 88% retinal sensitivity in the macula was also achieved. In the group of patients subjected to phacovitrectomy (Group 1 macular hole) with an average minimum hole diameter of 487.48 μm before the procedure, after a one-year follow-up the mean best corrected distance visual acuity was 0.57 and best corrected near visual acuity 0.51, with macular retinal sensitivity of 26.65 dB. However, in the group of patients subjected to combined cataract and vitrectomy, an average minimum hole diameter of 521.58 μm 12 months after trans pars plana vitrectomy was performed as well as an average best corrected distance visual acuity of 0.64, best corrected near visual acuity of 0.5, and retinal sensitivity in the macula of 25.98 dB. There were no statistically significant differences between phacovitrectomy and the combined procedures in terms of the improvement in the values of distance and near visual acuity and macular retinal sensitivity 12 months after trans pars plana vitrectomy. A statistically significant improvement in retinal sensitivity in the macula was observed in Group 1 macular hole during the 12-month follow-up, while in the combined procedure group the improvement was not statistically significant.

Conclusions: Vitrectomy is an effective method of treating maculopathy in the form of macular hole. Morphological and functional improvement was noted in all patients, regardless of the treatment method used. There were no statistically significant differences between phacovitrectomy and the combined procedure in terms of the improvement achieved in the values of distance visual acuity parameters, near vision and retinal sensitivity in the macula 12 months after trans pars plana vitrectomy. A common feature of patients with worse results on individual variables was a longer duration of the disease and a larger size of the hole prior vitrectomy.

Key words:

macular hole, phacovitrectomy, vitrectomy, microperimetry.

Introduction

Macular hole (MH) is an anatomical defect of all neuronal layers of the retina within the fovea [1], accompanied by swelling of the surrounding retinal tissue and a gradual loss of function of the surrounding photoreceptors as a result of pathological forces exerted on the retina within the fovea by the shrinking vitreous body [2].

Idiopathic macular hole is a relatively common cause of visual impairment, most often occurring in patients over 65 years of age (6th–8th decade of life) with an incidence of 7.8 new cases per 100,000 individuals per year [3], three times more frequent in females than in males [4–6]. Macular hole occurs unilaterally in 80% of cases [3, 7, 8]. Vitrectomy is the surgical method of choice for the treatment of full-wall macular holes, with an anatomical success rate of 85–100% [9–12]. The use of vitrectomy

with removal of the inner retinal limiting membrane (ILM) has now become the method of choice in the treatment of MH, and most authors report achieving closure of the hole with the success of 90–98% [13, 14]. Vitrectomy in the treatment of macular holes involves the removal of the entire vitreous body or only its central part (cortical pars plana vitrectomy), removal of the inner retinal limiting membrane and the use of intraocular gas tamponade. Since 2009, the surgical technique of the inverted ILM flap, which was first described by Michalewska et al. [15], has also been used. In the postoperative period, patients are recommended to adopt an appropriate body position – face down position (FDP) – in order to place the gas used for tamponade frontally to the hole [16, 17]. Cataract is a common complication after vitreoretinal procedures, especially those involving intraocular gas tamponade. It is estimated that 6 months after surgery, the exi-

sting cataract progresses in 34% of cases, and after 12 months in 50% of cases [18, 19]. Moreover, macular holes affect patients in the 6th–8th decade of life, where cataracts appear to be a common occurrence. Combined cataract extraction with vitrectomy should now be a preferred and prevalent procedure in the surgical treatment of MH.

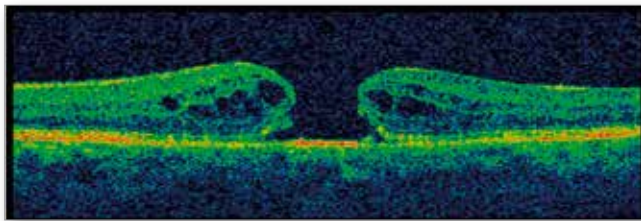


Fig. 1. OCT image – full-wall macular hole (stage IV).

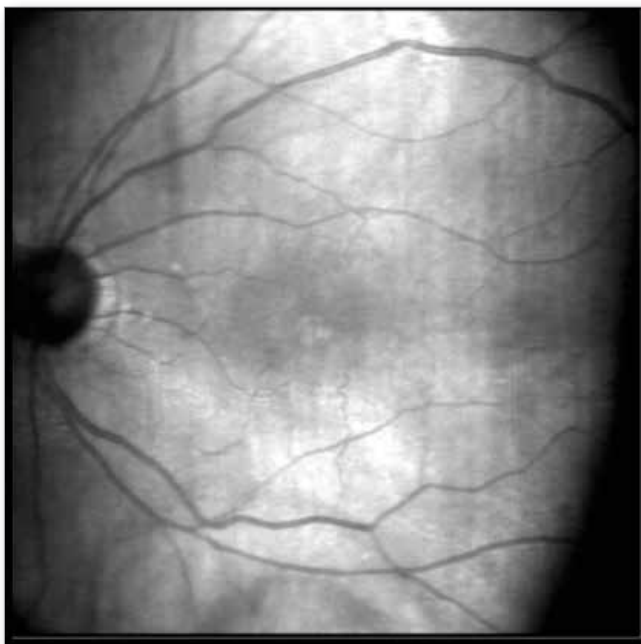


Fig. 2. Red-free image in macular hole microperimetry.

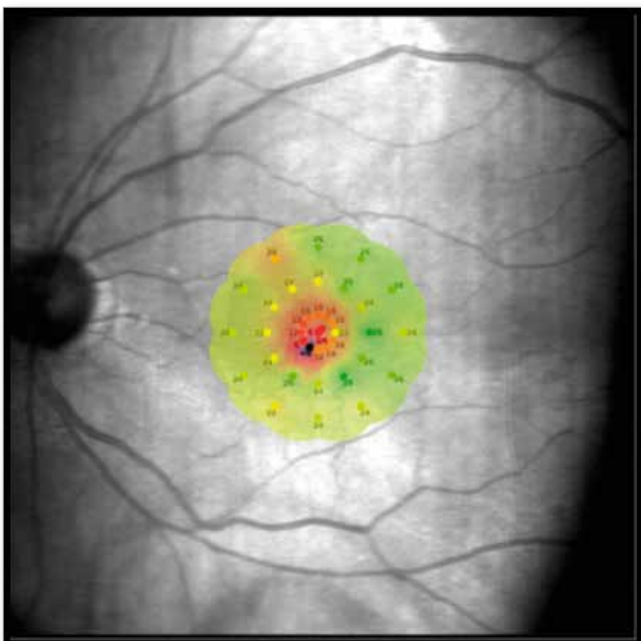


Fig. 3. Red-free image in macular hole microperimetry with a map of retinal sensitivity on the macular area.

Material and methods

The study group included 33 patients (33 eyes, 25 female patients and 8 males) with idiopathic macular hole. Initially, 35 patients (36 eyes) were included in the study group; however, due to the failure in closing the macular hole during primary vitrectomy in 3 cases, observations and analysis of the results were continued in 33 patients (33 eyes) due to the changed system of further follow-up and treatment. All patients underwent 23-gauge seamless vitrectomy with removal of the internal limiting membrane (ILM peeling), preceded by the administration of indocyanine green, and SF6 gas was used as an intraocular tamponade at an isovolumetric concentration of 20% and the recommended positioning for 7 days – face down. Cataract surgery was performed using the phacoemulsification method with an incision in the transparent part of the cornea with intracapsular, posterior chamber implantation of a monofocal lens. The inclusion criteria for the study were the diagnosis of an idiopathic, full-wall macular hole confirmed by spectral optical coherence tomography (SD-OCT), the patient's informed consent for participation in the study, and the visual acuity and general condition of the patients allowing the study to be performed. The preoperative exclusion criteria were: lack of consent for participation in the study, age-related macular degenerative changes, intense myopia and hyperopia, glaucoma, history of uveoretinitis, history of retinal vascular diseases and eyeball injuries, vascular bands and retinal breaks, choroidal tumors, developmental anomalies in the posterior pole, opacities of the optical centers making examination impossible, inflammatory diseases of the eye, previous intraocular and laser surgery and diabetes. Postoperative factors excluding patients from the group were an incomplete observation period and failure to close the macular hole due to a change in the treatment regimen and necessary follow-ups.

The study obtained a positive opinion from the Bioethics Committee of the Medical University of Lublin (KE-0254/51/2015). Twenty-one eyes were surgically treated with phacovitrectomy (Group 1 MH), and 12 patients underwent two-stage combined treatment with lens removal in the first stage and vitrectomy in the second (Group 2 MH). Cataract surgery was performed using the phacoemulsification method with an incision in the transparent part of the cornea with intracapsular, posterior chamber implantation of a monofocal lens. The average age of patients treated in one stage was 71.80 years, in two-stage treatment 67.85 years, and the statistical analysis showed that the average age of patients treated sequentially was statistically significantly lower ($p < 0.05$, $p = 0.04$). The duration of symptoms in patients treated in one stage was 13.86 months, while in two-stage treatment it was 11.42 months, which was not a statistically significant difference ($p > 0.05$, $p = 0.78$). In patients treated in one stage, tests were performed according to the following scheme: zero test (t_0), i.e. test on the day of phacovitrectomy, then postoperative tests were performed: 1 month (t_1), 3 months (t_2), 6 months (t_3), 12 months (t_4) after trans pars plana vitrectomy (TPPV), while in the two-stage treatment, the examination (t_0) was considered to be the examination on the day of lens removal surgery, on the day of vitrectomy (t_{01}), and postoperative examinations 1 month (t_1), 3 months (t_2), 6 months (t_3), and 12 months (t_4) after TPPV. At subsequent check-ups, the subjects underwent a full ophthalmological examination, which included: best corrected distance visual acuity (BCDVA) and best corrected near visual acuity (BCNVA) based on the Snellen chart, assessment of the anterior and posterior segments in a slit lamp, measurement of retinal sensitivity in the macula using microperimetry, the Amsler test, and optical coherence tomography (OCT) examination of the macular area.

Visual acuity for distance and near was tested using the Snellen chart. Distance visual acuity was tested from a distance of 5 m,

using a board with illuminated optotypes – letters (Chart Projector FR-1003LED by Frey) and a decimal scale. Near visual acuity (35 cm) was assessed using a reduced Snellen chart and a decimal scale, where the value of D-0.5 means full visual acuity and D-3.0 is the lowest that can still be examined on this chart. The stage of macular hole was assessed based on the Gass classification. Stage IV MH was diagnosed in 28 patients, stage III in 4 patients, and stage II in one patient. The assessment of retinal parameters to confirm the diagnosis at the first visit, as well as subsequent tests according to the follow-up scheme, were analyzed by imaging using the TOPCON 3D 2000 OCT device (3D scan 6 x 6 mm). Using the measurement option, retinal measurements were made using a “compass”, including a parameter describing the size of the macular hole – minimum hole diameter (MHD). The minimum linear size of the macular hole is measured at the narrowest point in the center of the retina of the measured hole.

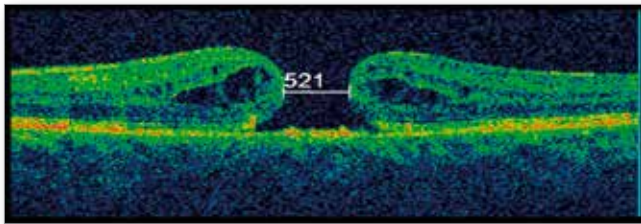


Fig. 4. Macular hole grade IV with MHD 521 μm .

Microperimetry was performed within 10° of the macular area (expert exam, protocol 4.2) using a Maia II device from Centevue to measure the sensitivity of the retina in the macula expressed in decibels (dB). Statistical analyses were used to evaluate the results. The distribution of the studied variables was checked using the Kolmogorov-Smirnov test. The values of the analyzed parameters measured on a ratio scale were characterized by mean, standard deviation, median (Me) and range of variability, while those measured on a nominal scale were characterized by frequency and percentage. Student’s t test or the Mann-Whitney test was used to assess differences between 2 groups for quantitative characteristics. Spearman’s rank correlation coefficient test was used to assess the impact of one quantitative variable on another quantitative variable, and the non-parametric Pearson’s chi-squared test was used for qualitative variables. To analyze changes occurring over time, the repeated-measures ANOVA test or the non-parametric Friedman’s rank-order ANOVA test and the Wilcoxon paired order test were used. The influence of 2 qualitative variables on a quantitative trait was analyzed based on the ANOVA test for factorial designs. An inference error of 5% and the associated significance level of $p < 0.05$ were assumed, indicating the existence of statistically significant relationships or differences. The database of analyzed data was created and statistical

analyses were carried out using Statistica 13.0 computer software (StatSoft, Poland).

Results

At time t_0 , BCDVA in Group 1 MH ranged from 0.05 to 0.4, with an average value of 0.14, while BCNVA ranged from 0.5 to 3.0, with an average value of 1.77, and the average retinal sensitivity in the macula averaged 22.48 dB. In patients from Group 2 MH at time t_0 BCDVA ranged from 0.04 to 0.2, with a mean of 0.12, and BCNVA from 0.75 to 3.0, with a mean value of 1.71 and mean macular sensitivity 23.92 dB (Tab. I). The Amsler test performed at t_0 for the presence of metamorphopsia was positive (+) in 33 patients (33 eyes, 100% of the subjects). During examination of the anterior segment under the slit lamp at time t_0 , as well as during subsequent check-ups, no significant pathology was found in any of the examined groups, apart from periodic irritation of the conjunctiva of the eyeball and slight inflammation of the eyelid margins. The OCT examination assessed the stage of MH based on Gass classification and measured the size of MHD. The mean MHD values at time t_0 did not differ statistically significantly between patients from Group 1 MH and 2 MH ($p > 0.05$) (Tab. II). In Group 1 MH, 18 patients had stage IV MH, two patients had stage III, one had stage II, and the average size of MHD was 478.48 μm . In Group 2 MH, macular hole was classified as stage IV in 10 patients and stage III in 2 patients. The mean MHD in the 2 MH group at time t_0 was 499.92, and t_{01} was 521.58 μm , and the observed difference was statistically significant ($p < 0.05$, $p = 0.02$) (Tab. III). In Group 2 MH, the waiting period between the first and second stages of treatment ranged from 1 to 5 months, and the average was 2.0 months. The tests at time t_{01} in patients treated with combined procedure were carried out after the first stage of treatment – lens removal surgery. They showed an improvement in BCDVA from an average of 0.12 to 0.15, BCNVA from 1.77 to 1.56, while the average retinal sensitivity in the macula dropped from 23.92 to 22.85 dB, and the obtained differences in the values of these parameters between time t_0 and t_{01} were not statistically significant (Tab. IV).

Parameters	Study in time t_0	
	Group 1. MH \bar{x}	Group 2. MH \bar{x}
BCDVA	0.14	0.12
BCNVA	1.77	1.71
Macular sensitivity	22.48 dB	23.92 dB

Tab. I. Test results of patients from Group 1 MH and 2 MH at time t_0 .

Type of measurement	1. MH t_0					2. MH t_0					Statistical analysis
	\bar{x}	SD	Me	Min	Max	\bar{x}	SD	Me	Min	Max	
MHD	487.48	199.75	485.00	235.00	876.00	499.92	114.07	521.00	275.00	653.00	Test t-Studenta $t = -0.20$; $p = 0.84$

Tab. II. MHD of the macular hole at time t_0 in 1 MH and 2 MH groups.

Patients from Group 2. MH	Mean	SD	Me	Q1	Q3	Wilcoxon paired order test
MHD t_0	499.92	114.07	521.0	445.5	595.5	
MHD t_{01}	521.58	112.02	532.0	460.0	617.5	$Z = 2.39$; $p = 0.02$

Tab. III. Comparison of the MHD parameter of patients from Group 2 MH between time t_0 and t_{01} .

Patients from Group 2. MH	Mean	SD	Me	Q1	Q3	Wilcoxon paired order test
Macular sensitivity t_0	23.92	1.78	24.30	21.60	25.30	Z = 0.98; p = 0.33
Macular sensitivity t_{01}	22.85	2.64	22.70	21.60	25.00	
BCNVA t_0	9.94	28.68	1.75	1.38	2.25	Z = 1.52; p = 0.13
BCNVA t_{01}	1.56	0.58	1.50	1.25	2.00	
BCDVA t_0	0.12	0.06	0.10	0.10	0.18	Z = 1.33; p = 0.18
BCDVA t_{01}	0.15	0.07	0.14	0.10	0.20	

Tab. IV. Comparison of test results of patients from Group 2 MH between time t_0 and t_{01} .

Method of treatment	BCDVA in time t_0		BCDVA in time t_1		BCDVA in time t_2		BCDVA in time t_3		BCDVA in time t_4		Statistical analysis	
	\bar{x}	SD	\bar{x}	SD	\bar{x}	SD	\bar{x}	SD	\bar{x}	SD	Repeated-measures ANOVA test	p
1. MH	0.14	0.09	0.27	0.18	0.44	0.22	0.54	0.21	0.57	0.21	F = 58.08 T0 vs. T1; T0 vs. T2; T0 vs. T3; T0 vs. T4; T2 vs. T4	0.00001
2. MH	0.12	0.06	0.33	0.11	0.49	0.10	0.58	0.12	0.64	0.14	F = 69.52 T0 vs. T1; T0 vs. T2; T0 vs. T3; T0 vs. T4; T1 vs. T3; T1 vs. T4; T2 vs. T4;	0.00001
MH	0.13	0.08	0.29	0.16	0.46	0.18	0.55	0.18	0.60	0.19	F = 117.3 T0 vs. T1; T0 vs. T2; T0 vs. T3; T0 vs. T4; T1 vs. T3; T1 vs. T4 T2 vs. T4;	0.0001

Tab. V. Results of BCDVA parameter tests in patients with MH, with division into treatment methods, during one-year follow-up.

Method of treatment	BCNVA in time t_0		BCNVA in time t_1		BCNVA in time t_2		BCNVA in time t_3		BCNVA in time t_4		Statistical analysis	
	\bar{x}	SD	\bar{x}	SD	\bar{x}	SD	\bar{x}	SD	\bar{x}	SD	Repeated-measures ANOVA test	p
1. MH	1.77	0.71	0.78	0.36	0.65	0.24	0.54	0.09	0.51	0.05	F = 52.97	0.001
2. MH	1.71	0.53	0.65	0.31	0.54	0.10	0.50	0	0.50	0	F = 56.29 *	0.0001
MH	1.73	0.49	0.73	0.22	0.61	0.09	0.52	0.11	0.51	0.19	F = 70.43 * T0 vs. T1; T0 vs. T2; T0 vs. T3; T0 vs. T4	0.001

Tab. VI. Results of the BCNVA parameter in patients with MH, divided by treatment method, during one-year follow-up.

Method of treatment	Macular sensitivity over time t_0		Macular sensitivity over time t_1		Macular sensitivity over time t_2		Macular sensitivity over time t_3		Macular sensitivity over time t_4		Statistical analysis	
	\bar{x}	SD	\bar{x}	SD	\bar{x}	SD	\bar{x}	SD	\bar{x}	SD	Repeated measures ANOVA test	p
1. MH	22.48	2.67	24.16	2.19	26.20	1.37	26.31	1.55	26.65	2.09	F = 4.22 T0 vs. T1; T0 vs. T2; T0 vs. T3; T0 vs. T4	0.005
2. MH	23.92	1.78	23.41	2.61	25.08	1.81	24.60	2.75	25.98	2.55	F = 2.33	0.075
MH	23.08	2.41	23.84	2.34	25.69	1.65	25.63	2.32	26.38	2.26	F = 5.63 0 vs. T5	0.004

Tab. VII. Results of macular retinal sensitivity tests in patients with MH, divided by treatment method, during one-year follow-up.

Based on the test results from individual follow-up investigations, it was found that both in one-stage and combined treatment and in the entire group of patients without division as for treatment method (MH group), one could observe a statistically significant increase in BCDVA and BCNVA values ($p < 0.05$) in the one-year follow-up (Tab. V, VI). Analyzing the values of microperimetry results, a statistically significant increase in retinal sensitivity in the macula was observed during the 12-month follow-up in 1 MH and without division into treatment method (MH

group) ($p < 0.05$) (Tab. VII). In 2 MH, there was an improvement in retinal sensitivity in the macula during the one-year follow-up, but this increase was not statistically significant. There was also a reduction in metamorphopsia at t_4 based on the Amsler test in both groups, with greater improvement in patients treated in one stage (Tab. VIII).

Summing up, the results of the one-stage and combined treatments were compared in terms of the improvement in test results obtained in the 12th month of observation compared to the exami-

Method of treatment	A after 12 m (-)	A after 12 m (+)	A after 12 m (minimal metamorphopsia)	Total
1. MH	11	10	0	21
%	52.38%	47.62%	0.00%	100.00%
2. MH	2	9	1	12
%	16.67%	75.00%	8.33%	100.00%
Total	13	19	1	33

Tab. VIII. Amsler test results (A) Group of patients with MH at t_1 .

Study groups	MH		
	average difference BCDVA	Sd	Me
1. MH	0.44	0.19	0.40
2. MH	0.52	0.14	0.53
Mann-Whitney Test Z = -1.29; p = 0.20			

Tab. IX. Results of a comparative analysis of BCDVA differences between t_1 and t_0 in patients with MH, divided by treatment method.

Study groups	MH		
	average difference BCNVA	Sd	Me
1. MH	-1.26	0.70	-1.00
2. MH	-1.27	0.63	-1.25
Mann-Whitney Test Z = 0.19; p = 0.85			

Tab. X. Results of a comparative analysis of BCNVA differences between t_1 and t_0 in patients with MH, divided by treatment method.

Study groups	MH		
	average difference in macular sensitivity	Sd	Me
1. MH	4.17	2.08	4.80
2. MH	2.06	2.75	2.95
Mann-Whitney Test Z = 1.82; p = 0.07			

Tab. XI. Results of a comparative analysis of differences in retinal sensitivity in the macula between time t_1 and t_0 in patients with MH, divided by treatment method.

nation prior vitrectomy, and no statistically significant differences were noted in the parameters BCDVA, BCNVA and retinal sensitivity in the macula (Tab. IX, X, XI).

Discussion

Maculopathy is a relatively common disease, most frequently occurring in patients over 65 years of age with an incidence of 7.8 new cases per 100,000 people per year [3], three times more frequent in females than in males [4–6]. MH occurs unilaterally in 80% of cases [3, 7, 8]. This is confirmed by the results of our research. The average age of patients in the study group was 70.24, 75% of the patients were female, and the disease was unilateral in 100%. Symptoms reported by patients diagnosed with MH include deterioration of visual acuity, mainly central, and image distortion in the form of metamorphopsia of varying intensity. All patients in the study had a positive (+) Amsler test for metamorphopsia before surgery. Currently, the most important diagnostic

tool in pathologies of the posterior pole of the eyeball, allowing for diagnosis, assessment of the stage of the disease, and assessment of treatment results, is OCT. Optical coherence tomography is an imaging method thanks to which the classification of macular holes has been refined and expanded, and it has also been possible to introduce precise terminology for vitreomacular borderline disorders, which was developed and published by a group of experts from the International Vitreomacular Traction Study Group (IVTS Group) [1]. In our study group, the stage of MH was assessed according to the Gass classification, which is based on the morphology of the holes. Over the years, authors have increasingly relied on the newer classification presented by the IVTS Group, which pays more attention to the border between the vitreous body and the macula [1]. In Group 1 MH, 18 patients had stage IV MH, 2 patients had stage III, and one had stage II, while in Group 2 MH, macular hole was classified as stage IV in 10 patients and stage III in 2 patients. Optical coherence tomography examination is currently an indispensable test to analyze the morphology of the retina (Fig. 5 and 6), while in order to assess its function, in addition to visual acuity, microperimetry is a very good complementary investigation which allows quantitative assessment of the function of the retina (Fig. 7 and 8).

Pars plana vitrectomies (PPV) used in the treatment of macular diseases are one of the most promising ophthalmological procedures. The first reports on surgical treatment techniques for this disease appeared in the 1990s. In vitreoretinal surgery for macular pathology, there are key variables relating to the removal of the internal limiting membrane (ILM peel), the choice of tamponade and chromovitrectomy dye, and the use of postoperative patient positioning. In the Department of Retina and Vitreous Surgery of the Medical University of Lublin, the standard treatment for macular hole has been 23-gauge vitrectomy with ILM peeling, preceded by the administration of brilliant blue G or indocyanine green, while triamcinolone is used to stain the vitreous body, and SF6 gas is used as a tamponade in isovolumetric concentration with the patient positioned face down position for up to 7 days after the procedure. However, in the case of very large, persistent macular holes, the “inverted flap” method is used.

The age of patients with macular pathologies and frequently co-occurring vitreous pathologies requires attention as for the presence of possible lens opacities. Globally, the prevalence of cata-

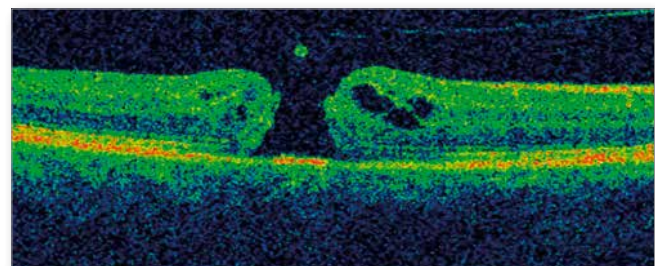


Fig. 5. OCT image of the macula of patient with MH in stage IV, with complete detachment of the posterior limiting membrane of the vitreous body with a visible lid.

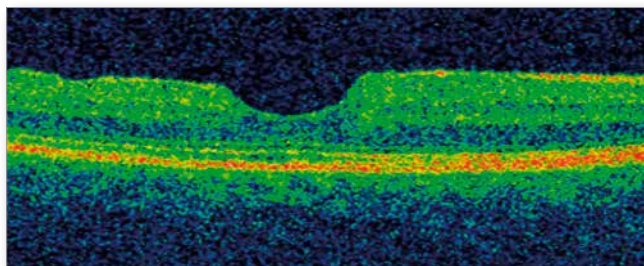


Fig. 6. OCT image of the same patient 12 months after TPPV with CFT 171 μm and good reconstruction of the IS/OS complex and ELM.

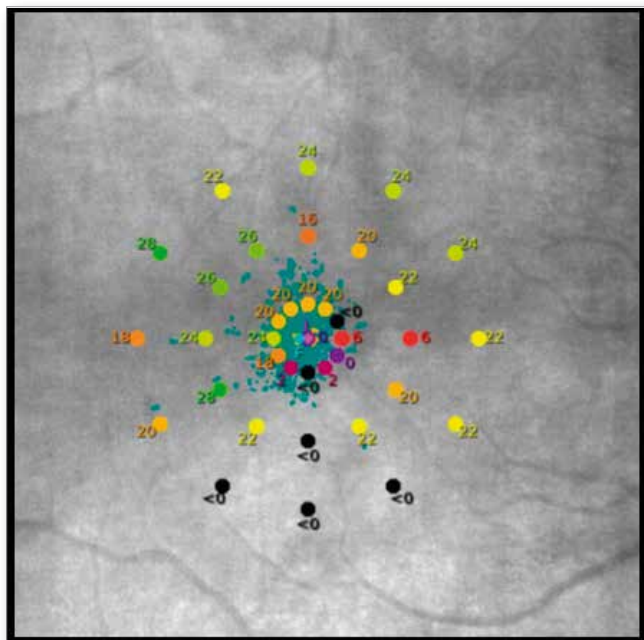


Fig. 7. Microperimetry result of patient showing a map of retinal sensitivity in the macula before phacovitrectomy.

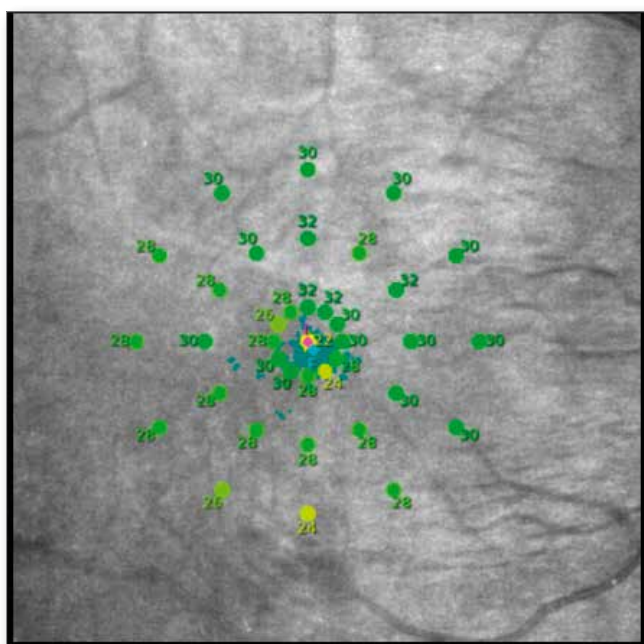


Fig. 8. Microperimetry result of patient, showing a map of retinal sensitivity in the macula 12 months after surgery.

tracts is estimated at 47.8% in people over 50 years of age [20], in Europe at the age of 60–69 it is 30%, and for individuals over 70 years of age it accounts for 64% [21]. A cataract may impair the view into the vitreous chamber and the visibility of details of the fundus of the eye during the procedure, which makes vitrectomy significantly more difficult. Moreover, faster occurrence of cataracts after vitrectomy is typical, especially after those procedures using gas or oil tamponade, and the quantitative differences result from the length of the postoperative observation period. Jackson et al. found that in nearly 60% of vitrectomy patients with various types of gas tamponade, cataract surgery was performed within 6 months after PPV [5]. The choice of treatment methods analyzed in this study is related to the fact that PPV in pseudophakic eyes is easier due to better visualization and access to the vitreous base and possible peripheral photocoagulation, which shortens the procedure time. Moreover, during TPPV in a pseudophakic eye, there is no risk of iatrogenic damage to the natural lens. However, cataract surgery in eyes after vitrectomy is technically more difficult due to the lack of stability of the posterior lens capsule and the greater risk of its rupture [22–24].

Moreover, extending vitrectomy in a pseudophakic eye by removing the anterior part of the vitreous body increases the gas volume in the vitreous chamber, which may have a beneficial effect on the anatomical effect in macular hole surgery [25]. In recent years, a procedure combining lens removal with vitrectomy has become increasingly popular. A combined procedure presents many advantages. First of all, patients do not require a second surgery and avoid possible complications related to it, secondly, the limitation of their activity is shorter, which also results in their faster rehabilitation [26]. Moreover, the course of the entire therapeutic process is not postponed, which has a positive effect on health. There are no analyses in the available literature based on prospective studies comparing the results of surgical treatment of macular hole with phacovitrectomy and two-stage, combined treatment. The analyses in this study were conducted prospectively, with a 12-month follow-up period after vitrectomy. It is also important that they were conducted in pseudophakic patients, which eliminated the influence of cataract progression on postoperative functional measurements. Due to the ongoing regeneration of photoreceptors, recovery of macular function may take time and is usually better with longer follow-up. In a multicenter UK database study of patients treated for MH, 48.6% of eyes achieved an improvement ≥ 0.3 LogMAR at 12 weeks postoperatively, and 58.3% after 52 weeks (5). This is confirmed by the results of our research. In both one-stage and two-stage treatment, we observed a statistically significant improvement in the BCDVA value in subsequent tests (Tab. V) during the 12-month follow-up, and the rate of increase in this parameter did not differ statistically significantly depending on the treatment method used. Kirshnan et al. [27] presented the results of studies after 23-gauge phacovitrectomy with ILM peeling, with a baseline visual acuity similar to ours, amounting to 0.89 logMAR, obtaining an improvement in BCVA on the LogMAR scale by an average of 0.52, which is a result similar to ours (0.44).

In the literature, patient's age is also mentioned as an important predictor of postoperative visual acuity, in addition to the size of the hole and preoperative visual acuity. The mean age of patients in Group 1 MH was statistically significantly higher compared to Group 2 MH ($p = 0.04$) (71.80 years vs. 67.85). Moreover, taking into account patients with MHD $> 500 \mu\text{m}$, in Group 1 MH the average age of these patients was 72.67, with an average MHD of 680.89 μm , while in Group 2 MH the average age was 67.71 years, with MHD 576.71 μm . The duration of symptoms was also longer in the 1 MH group (13.86 months vs. 11.42 months), but this difference was not statistically significant

($p = 0.78$). Taking into account the above data, it can be concluded that the lower postoperative distance visual acuity in patients treated in one stage was statistically significantly influenced by older age and longer duration of symptoms, and that patients with MHD > 500 μm constituted 50% of this group, with an average MHD of 680.89 μm , with 58% of patients in the 2 MH group with a mean MHD of 576.71 μm . Analyzing the best-corrected near visual acuity during the 12-month follow-up, it was found that both in Group 1 MH and Group 2 MH, there was a statistically significant improvement in this variable during the one-year follow-up (in Group 1 MH from mean 1.77 to 0.51, and in Group 2 MH from mean 1.71 to 0.5), achieving improvement in all patients, which also indicates a relationship between macular regeneration and time [6]. When comparing the increase in the BCNVA parameter in individual time periods, no statistically significant differences were found between the treatment methods used (ANOVA test with repeated measurements $F = 0.23$; $p = 0.92$). The difference in this parameter between the examination at time t4 and t0 in Group 1 MH was 1.26 (mean BCNVA at time t4 0.51), in Group 2 MH 1.27 (mean BCNVA at time t4 0.5); these were not statistically significant differences between the methods used ($p = 0.85$), though. Taking into account the results of microperimetry, 88% of operated patients who underwent the test had improved retinal sensitivity in the macula.

Analyzing this parameter at individual follow-up points, a statistically significant increase in this variable over time was observed in patients who underwent a one-stage procedure ($p = 0.005$). In the 1 MH group, there was a greater improvement in retinal sensitivity in the macula by an average of 4.17 dB, and it was 26.65 dB at t4 compared to patients treated in two stages with an average improvement of 2.06 dB and retinal sensitivity in the macula at t4 of 25.98 dB. However, these differences were not statistically significant ($p = 0.07$). The smaller increase in this parameter in the 2 MH group can be explained by the fact that initially the average value of retinal sensitivity in the macula in this group was higher (23.92 dB vs. 22.48 dB). Taking into account the above analyses, comparing the size of changes in parameters postoperatively related to the preoperative state (difference between examination t4 and t0), there were no statistically significant differences between the results of patients with MH treated with the one-stage and two-stage method, with respect to the values of the severity variables, distance and near vision, and retinal sensitivity in the macula. However, taking into account changes in parameter values over time (based on measurements at successive time points during a one-year follow-up), statistically significant differences between the treatment methods used were observed in relation to the sensitivity of the retina in the macula among patients undergoing phacovitrectomy.

Summing up, the postoperative visual acuity of patients with a macular hole was influenced by the patient's age, initial size of the hole, and duration of symptoms. In the case of a macular hole, the duration of this pathology affects the size of the hole, which in turn has predictive significance for parameters assessing retinal function after surgery [9, 28, 29]. In our patients with MH, the longer duration of the disease resulted in an increase in hole size parameters, which correlated with worse postoperative distance and near visual acuity, as well as retinal sensitivity in the macula. Both treatment methods are effective in achieving functional and anatomical improvement. A common feature of patients with worse results on individual variables was a longer duration of the disease. Phacovitrectomy regarding its singularity as a procedure therefore reduces the risk of possible complications during the next procedure, makes the therapeutic process and patient's convalescence faster and is also associated with a lower financial and mental burden, lower costs of the procedure, and optimization

of the work of the staff and the operating theater. Better health effects resulting from previously performed surgery indicate that choosing a one-stage method is more beneficial.

Conclusions

Vitrectomy is an effective method of treating maculopathy in the form of macular hole. There were no statistically significant differences in the improvement in the variables BCDVA, BCNVA, retinal sensitivity in the macula between the one-stage method (phacovitrectomy) and sequential, two-stage, combined treatment (in the first stage, removal of the lens; in the second, vitrectomy) in patients with a macular hole. Phacovitrectomy, joining lens removal and vitrectomy, seems to be a safe alternative to two-stage treatment of macular pathology.

Disclosure

Conflict of interests: none declared

Funding: no external funding

Ethics approval: The study was approved by the Bioethics Committee of Medical University of Lublin (KE-0254/51/2015).

References:

- Duker JS, Kaiser PK, Binder S, et al.: *The International Vitreomacular Traction Study Classification System for Vitreomacular Adhesion, Tractation, and Macular Hole*. Ophthalmology. 2013; 120: 2611–2619.
- Wylegala E, Nowińska A, Teper S: *Optyczna Koherentna Tomografia II*. Górnicki Wydawnictwo Medyczne, Wrocław 2010, s. 71–80.
- McCannel CA, Ensminger JL, Diehl NN, et al.: *Population based incidence of macular holes*. Ophthalmology. 2009; 116: 1366–1369.
- Wang S, Xu L, Jonas JB: *Prevalence of full thickness macular holes in urban and rural adult Chinese: the Beijing Eye Study*. Am J Ophthalmol. 2006; 141: 589–591.
- Jackson TL, Donachie PH, Sparrows JM, et al.: *The United Kingdom National Ophthalmology Database study of vitreoretinal surgery: report 2, macular hole*. Ophthalmology. 2013; 120(3): 629–634.
- Rubowitz A: *Classification of macular holes*. Ophthalmology. 2007; 114: 1956–1957.
- Chew EY, Sperduto RD, Hiller R, et al.: *Clinical course of macular holes. The Eye Disease Case-Control Study*. Arch Ophthalmol. 1999; 117: 242–246.
- Johnson MW, van Newkirk MR, Meyer KA: *Perifoveal vitreous detachment is the primary pathogenic event in idiopathic macular hole formation*. Arch Ophthalmol. 2001; 119: 215–222.
- Gupta B, Laidlaw DA, Williamson TH, et al.: *Predicting visual success in macular hole surgery*. Br J Ophthalmol. 2009; 93: 1488–1491.
- Passemard M, Yakoubi Y, Muselier A, et al.: *Long-term outcome of idiopathic macular hole surgery*. Am J Ophthalmol. 2010; 149: 120–126.
- Kirshnan R, Tossounis C, Yang YF: *20-gauge and 23-gauge phacovitrectomy for idiopathic macular holes: comparison of complications and long-term outcomes*. Eye. 2013; 27: 72–77.
- Michalewska Z, Michalewski J, Nawrocki J: *Macular hole closure after vitrectomy: the inverted flap technique*. Retina Today. 2009; 3: 73–74.
- Beutel J, Dahmen G, Ziegler A, et al.: *Internal limiting membrane peeling with indocyanine green or trypan blue in macular hole surgery: a randomized trial*. Arch Ophthalmol. 2007; 125: 326–332.
- Brooks HI Jr.: *Macular hole surgery with and without internal limiting membrane peeling*. Ophthalmology. 2000; 107: 1939–1949.
- Michalewska Z, Michalewski J, Adelman RA, et al.: *Inverted internal limiting membrane flap technique for large macular holes*. Ophthalmology. 2010; 107: 2018–2025.
- Lee JW, Kim IT: *Outcomes of idiopathic macular epiretinal membrane removal with and without internal limiting membrane peeling: a comparative study*. Jpn J Ophthalmol. 2010; 54(2): 129–134.
- Bernardos RL, Barthel LK, Meyers JR, et al.: *Late-stage neuronal progenitors in the retina are radial Müller glia that function as retinal stem cells*. J Neurosci. 2007; 27(26): 7028–7040.
- Jaycock PD, Bunce C, Xing W, et al.: *Outcomes of macular hole surgery: implications for surgical management and clinical governance*. Eye (Lond.) 2005; 19: 879–884.

19. Wong SC, Clare G, Bunce C, et al.: *Cataract progression in macular hole cases: results with vitrectomy or with observation*. J Cataract Refract Surg. 2012; 38: 1176–1180.
20. Resnikoff S, Pascolini D, Etya'ale D, et al.: *Global data on visual impairment in the year 2002*. Bull World Health Organ. 2004; 82: 844–851.
21. Prokofyeva E, Wegener A, Zrenner E: *Cataract prevalence and prevention in Europe: a literature review*. Acta Ophthalmol. 2013; 91(5): 395–405.
22. Ghosh S, Best K, Steel DH: *Lens-iris diaphragm retropulsion syndrome during phacoemulsification in vitrectomized eyes*. J Cataract Refract Surg. 2013; 39: 1852–1858.
23. Lee JY, Kim KH, Shin KH, et al.: *Comparison of intraoperative complications of phacoemulsification between sequential and combined procedures of pars plana vitrectomy and cataract surgery*. Retina 2012; 32: 2026–2033.
24. Rejdak R: *Wskazania do witrektomii*. Via Medica, Gdańsk 2017, s. 67. ISBN 978-83-65797-07-0.
25. Scartozzi R, Bessa AS, Gupta OP, et al.: *Intraoperative sclerotomy-related retinal breaks for macular surgery, 20-versus 25-gauge vitrectomy systems*. Am J Ophthalmol. 2007; 143: 155–156.
26. Muselier A, Dugas B, Burelle X, et al.: *Macular hole surgery and cataract extraction: Combined vs consecutive surgery*. Am J Ophthalmol. 2010; 150: 387–391.
27. Krishnan R, Tossounis C, Yang YF: *20-gauge and 23-gauge phacovitrectomy for idiopathic macular holes: comparison of complications and long-term outcomes*. Eye. 2013; 27: 72–77.
28. Ruiz-Moreno JM, Arias L, Araiz J, et al.: *Spectral-domain optical coherence tomography study of macular structure as prognostic and determining factor for macular hole surgery outcome*. Retina. 2013; 33: 1117–1122.
29. Michalewska Z, Michalewski J, Nawrocki J: *Diagnosis and evaluation of macular hole with the HRT 2 retina module*. Ophthalmologe. 2007; 104: 881–888.

Contact and reprint request:

Kinga Tochman-Kanty, MD (e-mail: k.tochman@wp.pl)
Klinika Chirurgii Siatkówki i Ciała Szklistego Uniwersytetu Medycznego w Lublinie
ul. Chmielna 1 (Uniwersytecki Szpital Kliniczny Nr 1), 20-079 Lublin