

# Evaluation of Heavy Silicon Oil in the Treatment of Retinal Detachment Mainly Involving Lower Quadrants

Adam Cywiński

Silesian Eye Treatment Centre in Żory, Poland

## Abstract:

**Introduction:** The article presents a retrospective analysis of postoperative, anatomic results, including complications in a group with diagnosed primary and recurrent retinal detachment, involving the lower quadrants, where heavy silicon oil was used.

**Material and methods:** Heavy silicone oil was injected in 53 eyes in 51 patients. In most cases combined procedures were performed, including lens removal, removal of cerclage or iris reconstruction.

**Results:** Retinal attachment was finally achieved in 88.5% of cases in the eyes with diagnosed primary retinal detachment and in 77.7% in the group with recurrent retinal detachment. Statistically significantly more retinotomies were performed in the eyes with recurrent retinal detachment. Residual peripheral vitreous required removal during repair surgery in the eyes with recurrent retinal detachment. In the eyes with postoperative aphakia a modification of Ando iridotomy was performed.

**Conclusions:** Heavy silicon oil should be used as the endotamponade of choice, in eyes where the cause of retinal detachment is located in lower quadrants and cannot be effectively treated using another form of endotamponade because of low and unpredictable postoperative effectiveness. Location of the cause of retinal detachment should constitute the main criterion of choosing of the right kind of endotamponade.

## Key words:

heavy silicon oil, retinal detachment, Densiron®, Ando iridotomy, retinotomy, plastic of the iris.

## Introduction

“Heavy” silicone oil is a common name for a mixture the specific gravity of which is greater than that of water. Its only “representative” available in Poland is Densiron® by Geuder. Densiron, which is a mixture of perfluorohexylacetane and silicone oil, has two extremely useful properties that are of great importance in retinal surgery. The first is the mentioned high specific gravity, and the second is the lack of emulsification. Therefore, this oil adheres more strongly to the retina in its lower quadrants, but also partially in its upper quadrants. This distinguishes “heavy” oil from “light” silicone oils, regardless of their viscosity.

The lack of emulsification is a desirable feature if there is a need to leave the oil in the eye for a longer period [1]. Emulsification of silicone oil is one of the main causes of secondary glaucoma, so the option to avoid it allows not only the correct eye pressure to be maintained, but also its later consequences to be avoided [2].

Referring to the manufacturer’s indications regarding the use of Densiron® XTRA heavy silicone oil, they include not only retinal detachments, which are located in lower quadrants, but also those in the posterior pole of the eyeball. Other manufacturer’s suggestions for its use include:

- retinal detachment with giant tear,
- retinal detachment accompanied by vitreoretinopathy,
- retinal detachment associated with eye complications of diabetes,
- post-traumatic retinal detachment [1].

Taking into account the properties of heavy oil and the author’s own experience, further indications include surgery for a macular hole or retinal detachment in the posterior pole (e.g. high myopia accompanied by retinal and choroid atrophy), if it is impossible to maintain a forced position, i.e. tilted towards the ground.

The benefits of using heavy oil have been described in many articles.

Auriol et al. demonstrated its effectiveness in retinal attachment at 92.5% in the treatment of 27 eyes with diagnosed recurrent retinal detachment previously treated by performing giant

retinotomy in lower quadrants [3]. In another study, including 49 cases treated for recurrent retinal detachment in lower quadrants, permanent retinal attachment was achieved in 61.2%. Re-performing the retinal attachment procedure improved this result to 81.6%, but the presence of heavy oil did not guarantee its permanent attachment [4]. Both of the above studies describe the effects of using heavy oil in eyes treated for recurrent retinal detachment. Romano et al. describes the postoperative effect in eyes with primary giant rhegmatogenous retinal detachment. Densiron®-68 was administered to 41 eyes, achieving retinal attachment in 91% after just one treatment, and in 94% after another treatment [5]. Moussa et al. decided to compare the results of treatment of primary rhegmatogenous retinal detachment using “light” oil to those treated using Densiron®. The procedure was performed in 259 eyes, where heavy oil was used in 80 eyes. Postoperative outcomes, both in terms of benefits and adverse effects, were comparable. Glaucoma was diagnosed in a similar number of cases – 5 eyes (2.8%) in the case of “light” oil and 4 eyes (5.0%) in the case of heavy oil – which, taking into account the greater number of procedures using light oil, indicates a less unfavourable effect after the procedure when using “heavy” oil.

On the other hand, the authors draw attention to a statistically significantly higher percentage of retinotomies performed in the eyes with “light” oil [6].

The mentioned postoperative complications after the use of heavy oil include: appearance of fibrin in the anterior chamber, glaucoma requiring treatment, and increase in eye pressure immediately after the procedure [2–6]. Based on the assessment of 27 eyes, Li et al. drew attention to the progression of cataracts, opacification of the posterior capsule, and inflammation [7].

Taking into account the author’s own experience, one should remember to maintain the appropriate postoperative position, different from that used after administering “light” silicone oil, and in the case of surgery in an aphakic eye, peripheral iridotomy should be performed in the upper part of the iris, contrary to what is done in the case of modo Ando iridotomy.

## Objective

Retrospective analysis of the results of the treatment of primary and recurrent retinal detachment in terms of the anatomical effect obtained, i.e. retinal attachment and postoperative complications after the use of heavy silicone oil.

## Material and methods

The procedures were performed between 2018 and 2023 in 51 patients (53 eyes). Densiron® by Geuder was used in each case. The procedures were performed by one surgeon at a private medical centre, the Silesian Eye Treatment Centre in Żory, as standard as one day surgery.

## Eligibility for the use of endotamponade using heavy silicone oil

The patients were divided into two groups: with primary (group 1) and recurrent (group 2) retinal detachment.

Primary retinal detachment: retinal detachment with numerous holes on the extreme and middle periphery, or one giant tear in lower quadrants.

Secondary retinal detachment: recurrent or residual retinal detachment in lower quadrants, in eyes with endotamponade performed using “light” silicone oil or after administration of expansile gas, including in eyes after retinotomy; conditions after posterior vitrectomy or after extraocular surgery to reattach the retina.

Most posterior vitrectomy procedures were combined with other surgical procedures.

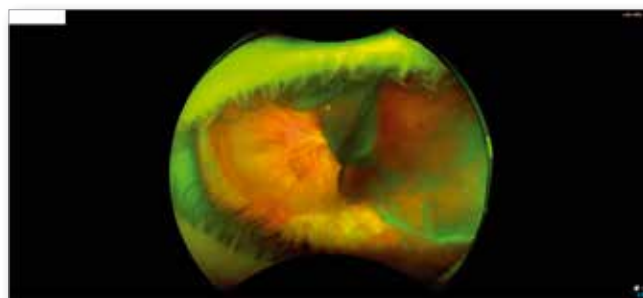
The most important eligibility criterion is an appropriately quick response time, i.e. performing repair surgery, including in the event of recurrent retinal detachment. The presence of residual retinal detachment in lower quadrants lasting longer than 10–14 days or diagnosing retinal detachment during a subsequent, even unplanned appointment (e.g. one month after the procedure) constituted an indication for urgent retinal reattachment surgery in patients from group 1.

The causes of retinal detachment, concomitant diseases and the number of eyes, divided into groups, i.e. group 1 (primary retinal detachment) and group 2 (recurrent retinal detachment) are presented in Table I.

Cause of retinal detachment and concomitant diseases	Group 1 (number of eyes)	Group 2 (number of eyes)
Large tears or holes in lower quadrants	5	4
Injury	10	4
Peripheral vitreous not removed	0	6
Stickler syndrome	2	2
Von Hippel-Lindau syndrome		2
High myopia	2	8
Giant medullary fibres	2	
Idiopathic macular hole		1
Ocular complications of prematurity	1	
Recurrent uveitis	1	
AMD – massive subretinal haemorrhage	1	
Ocular complications of diabetes	2	
Total number of eyes	26	27

**Tab. I.** Causes of retinal detachment, concomitant diseases and number of eyes, divided into groups, i.e. group 1 (primary retinal detachment) and group 2 (recurrent retinal detachment).

It is worth paying attention to several values in the table above. The most common cause of retinal detachment is an eye injury. The most common factor associated with recurrent retinal detachment was high myopia. In six eyes with recurrent retinal detachment the peripheral vitreous was not completely removed. In the case of recurrent retinal detachment eyes with quite rare diseases dominated, for which standard treatment is often ineffective. This applies to Stickler syndrome, in which the retina has a very non-standard structure, and to giant medullary fibres that largely cover the posterior pole of the eyeball (Fig. 1).



**Fig. 1.** Wide-angle colour fundus photograph (OPTOS). An 8-year-old child, left eye. Primary retinal detachment not resulting from a specific cause but associated with Stickler syndrome. A giant spontaneous tear is seen temporally, between the posterior pole and the midperiphery, between 1 and 6 o'clock, thus separating the posterior pole from the peripheral retina. Eye without the vitreous body. The peripheral retina has the structure of an openwork fabric.

Given the wide variety of causes of retinal detachment in many cases procedures were performed in which retinal reattachment was combined with one or more other surgical procedures.

Type of procedures performed, including combined procedures, as well as the condition of the lens diagnosed in group 1 (primary retinal detachment), are included in Table II (below).

Number of eyes (patients)	26 (24)
PPV + D	12
PPV + D + S (macular detachment)	4
PPV + D + S + W	5
PPV + D + P	2
PPV + D + O	2
PPV + D + R	1
Pseudophakia	11
Natural lens	6

PPV – posterior vitrectomy, D – Densiron, S – lens removal without implant, S + W – lens removal with implant, P – pupil size reduction, O – buckling, R – retinotomy

**Tab. II.** Type of procedures performed, including combined procedures, as well as the condition of the lens diagnosed in group 1, with primary retinal detachment.

In four eyes, posterior vitrectomy with endotamponade was combined with removal of the natural lens and subsequent implantation of an artificial lens. This procedure was not performed in another three eyes because the detachment concerned the macula and it was not possible to precisely calculate the lens. In two children, posterior vitrectomy was combined with removal of the scleral band due to its imprecise and therefore ineffective application.

In one case, a simultaneous procedure was performed to reduce the pupil size, also performing reverse iridotomy, a modification of the modo Ando procedure.

The type of procedures performed, including combined procedures, as well as the condition of the lens diagnosed in group 2,

including eyes with recurrent retinal detachment, involving the lower quadrants, are presented in Table III (below).

<b>Number of eyes (patients)</b>	<b>27</b>
Peripheral PPV + D	6
PPV + D + S	2
PPV + D + P	1
PPV + D + R	3
<b>Number of retinotomies performed during the previous procedure</b>	<b>8</b>
Pseudophakia	22
Natural lens	3

PPV – posterior vitrectomy, D – Densiron, S – lens removal without implant, S + W – lens removal with implant, P – pupil size reduction, O – buckling, R – retinotomy

**Tab. III.** Type of procedures performed, including combined procedures, as well as the condition of the lens diagnosed in group 2, including eyes with recurrent retinal detachment in lower quadrants.

There was a significant difference in the number of retinotomies performed in lower quadrants. In this group, the total number of retinotomies was eleven, of which eight were performed during previous procedures, compared to one retinotomy performed in the group with primary retinal detachment.

An additional element that had a negative impact on the final effect of the procedure was leaving the peripheral vitreous body during primary vitrectomy, which was removed in six eyes.

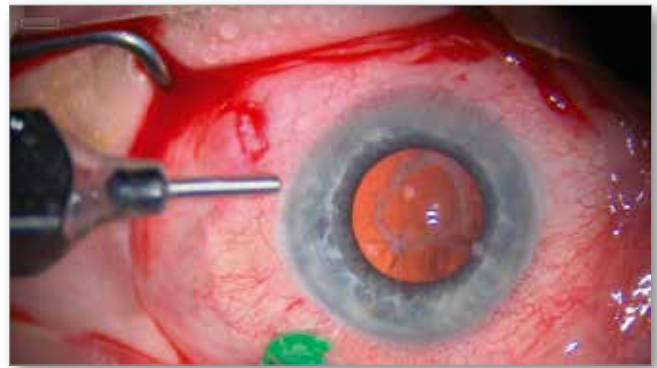
### Technique of administering and removing heavy oil from the inside of the eye

**Oil administration.** It is preceded by the removal of fluid or perfluorodecalin, and filling the vitreous chamber with air. Due to the ease of introducing the oil into the eye, manual and mechanical administration can be performed using both 23G and 20G cannulas. In aphakic eyes, before administering the oil, a modification of modo Ando iridotomy should be performed, keeping in mind the fact that the oil will be located below the fluid produced by the eye.

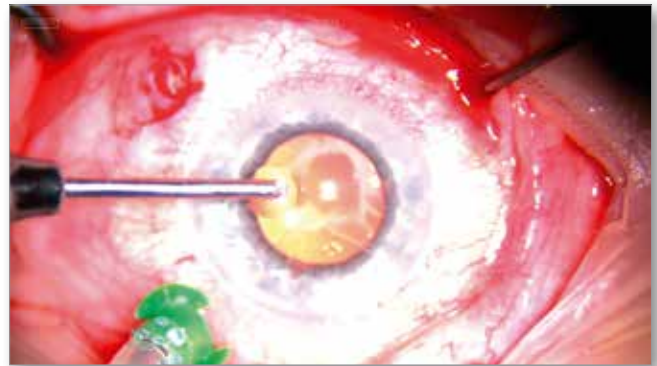
**Oil removal.** This is the fastest procedure, taking only a few minutes, much less time than the removal of light oils. Oil removal is performed using 20G cannulas of various lengths. Initially, the shortest cannula (0.75 cm) is used to administer the oil, followed by a longer cannula (1.5 mm). In rare cases, in the event of very high myopia, a 30 mm long cannula is used to remove residual oil from the eye (Fig. 2A, B).

If a 23G or 25G cannula is used, the oil removal procedure is significantly longer.

The average time of oil removal from the eye in the study group, from the moment of its administration, is 12 weeks, ranging from 2 to 24 weeks.



**Fig. 2A.** Colour photograph taken intraoperatively, showing the length of the shortest cannula, 20G (length = 0.75 cm), which is used to remove the oil at the first stage, just before it is inserted into the eye.



**Fig. 2B.** The same procedure, another stage of heavy oil removal using a cannula approximately 1.5 cm long, in most cases allowing for complete removal of the oil from the eye.

### Results

The average postoperative follow-up period was 19 months, ranging from 6 to 60 months.

Information about the condition of the retina after the procedure and whether the oil was removed or remained in the eye, divided into both groups, is presented in Table IV.

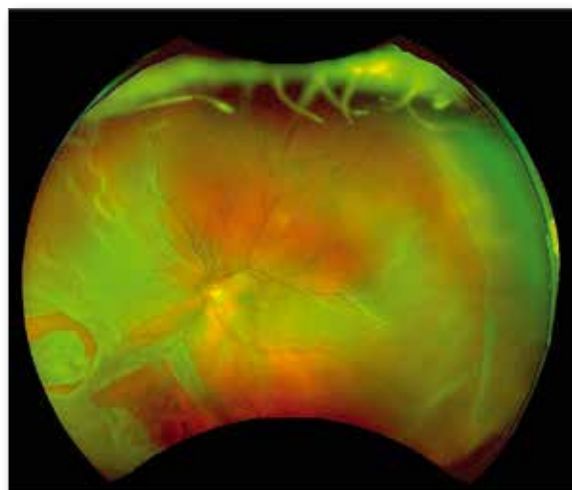
The study clearly showed that in group 1 the effect of retinal attachment was achieved after a single administration and subsequent removal of heavy oil in over 80% of the eyes compared to less than 60% in group 2 (Fig. 3A, B, C).

During heavy oil removal, in group 1 an additional procedure was performed, i.e. laser therapy with the administration of expansile gas in 2 eyes (7.7%) due to the appearance of retinal detachment, located in upper quadrants. In the group with recurrent retinal detachment, a similar procedure was performed in 5 eyes.

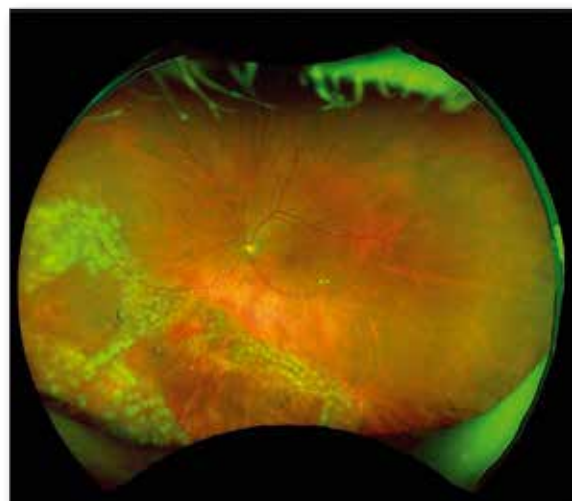
Retinal attachment with subsequent oil removal was not achieved in 3 eyes (11.5%) in group 1 compared to twice as many eyes, i.e. 6 (22.3%), in group 2 (Fig. 4A, B).

<b>Retinal condition after administration of heavy silicone oil</b>	<b>Group 1 Primary retinal detachment Number of eyes / %</b>	<b>Group 2 Recurrent retinal detachment Number of eyes / %</b>
Retina was attached, oil was removed after one treatment	21 (26) = 80.8%	16 (27) = 59.2%
Retina was attached, but during oil removal, additional laser therapy was performed and expanding gas was administered	2 (26) = 7.7%	5 (27) = 18.5%
Retina was finally attached after silicone oil removal	23 (26) = 88.5 %	21 (27) = 77.7%
Retina was still detached, oil was not removed	3 (26) = 11.5 %	6 (27) = 22.3 %

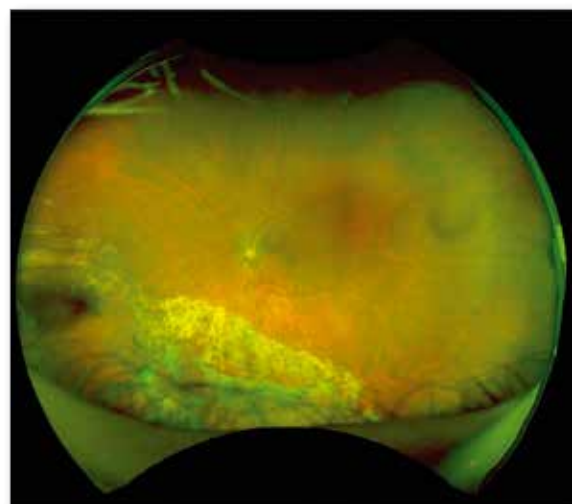
**Tab. IV.** Information about the condition of the retina after the procedure and whether the oil was removed or remained in the eye, divided into both groups.



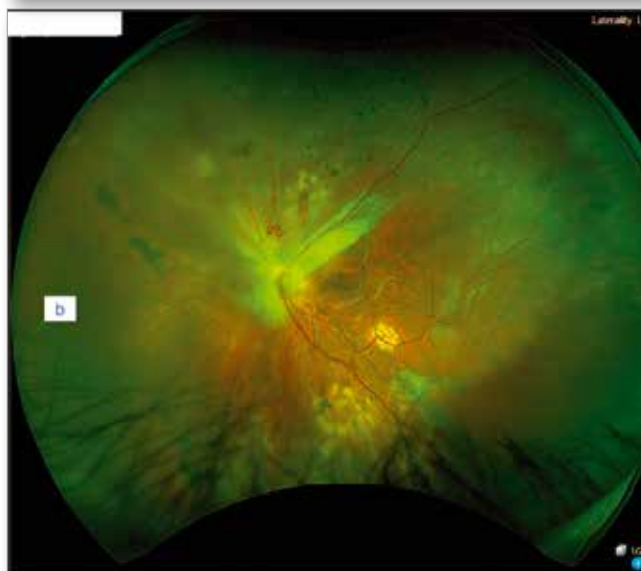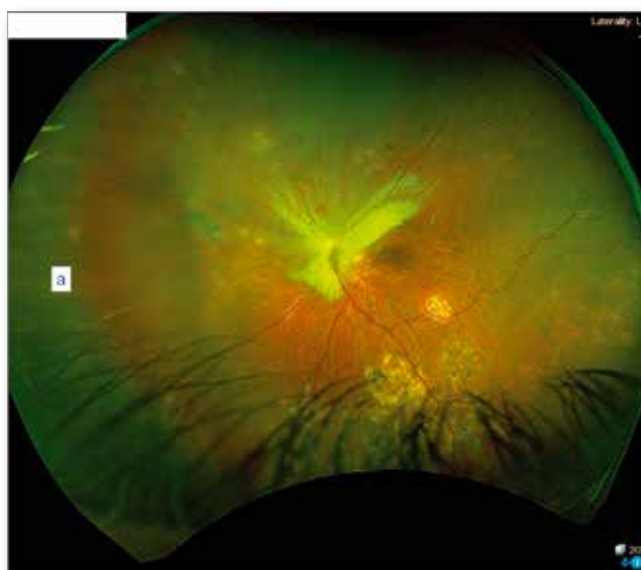**Fig. 3A.** Wide-angle colour fundus photograph (OPTOS). A 56-year-old man, left eye. Primary, complete, rhegmatogenous retinal detachment with giant holes in lower quadrants.



**Fig. 3B.** Wide-angle colour fundus photograph (OPTOS). The same eye on the 8<sup>th</sup> day after posterior vitrectomy with heavy silicone oil. Note the presence of "white" post-laser lesions surrounding the holes, located only in the area of tears (standard procedure for laser technique). Over time, usually after 7–14 days, the places after the use of the laser will become discoloured, which will constitute clear information about the formation of a scar.



**Fig. 3C.** Wide-angle colour fundus photograph (OPTOS). The same eye 4 months after the procedure, one month after oil removal. The retina is fully attached. Numerous scars after laser therapy are visible in lower quadrants.



**Fig. 4.** Wide-angle colour fundus photographs (OPTOS) of the same patient. A 42-year-old man, recurrent retinal detachment in the eye with giant medullary fibres around optic disc II and in the upper nasal quadrant. Visible traces of laser therapy in lower quadrants, at the site of the original detachment. A. 1 day after removal of heavy oil – the retina is attached, B. 7 days after removal of the oil – recurrent retinal detachment in the projection of medullary fibres; the retina was subjected to laser therapy in the projection of medullary fibres, the vitreous chamber was filled with light oil.

The reasons for the inability to remove the oil and therefore for recurrent retinal detachment in group 1 include Stickler syndrome, giant medullary fibres and failure to obtain a permanent retinohoroidal scar. In these eyes, additional procedures were performed to reattach the retina, and therefore these eyes were also included in group 2.

In group 2, the main cause was recurrent retinal detachment in monocular subjects (2 eyes) and at least two previous retinal attachment procedures. In these eyes, giant retinotomies were performed and additional hypotony was observed. Of the remaining four cases, two causes were included in group 1.

From the author's own observations, in eyes in which the fundus is very light and with a small amount of pigment, it is often not possible to obtain a permanent retinohoroidal scar, and there are often signs of vitreoretinopathy and even inflammatory irritation of the uvea caused by laser therapy. This condition was observed in one eye in group 1 and in two eyes in group 2.

## Complications

Early and late postoperative complications are presented in Table V.

Cause	Number of eyes
Transient increase in intraocular pressure	22
Very high intraocular pressure that cannot be reduced with topical or systemic medications	1
Very high intraocular pressure, oil in the anterior chamber, eye after fixation of an artificial lens	1
Oil in the anterior chamber	2

**Tab. V.** Early and late postoperative complications.

A transient increase in intraocular pressure in the eye is the most common complication, often reaching values up to 40 mmHg. The use of pressure-lowering drops and the 3-day administration of dorzolamide at a dose of 3 x 1/2 tablet/ per day resulted in the normalization of intraocular pressure, most often assessed one week after the initiation of treatment.

It is worth adding that such high intraocular pressure was not caused by the injection of an excessive amount of silicone oil. To obtain the effect of attaching the retina, the eye does not have to be "pumped" with oil, as one would do with a ball. Leaving the eye even with very low intraocular pressure values should be the standard in the use of endotamponade using silicone oil. The eye can be left with intraocular pressure values that are higher than normal if the subretinal fluid has not been completely removed (author's note).

In one case, despite the implementation of the above-mentioned treatment, normalization was not achieved. The oil was removed 14 days after its introduction, without any negative impact on the condition of the detached retina.

In another case, after performing the reverse modo Ando iridotomy procedure, the eye pressure was normalized and the silicone oil was removed from the anterior chamber of the eye, in which an intraocular lens was implanted due to the lack of the capsule.

In the case of an excessively large drop of oil appearing in the anterior chamber, which had a negative impact on the quality of vision and visual acuity, the oil was removed after administering pilocarpine hydrochloride eye drops.

## Discussion

Is it worth using heavy silicone oil to treat retinal detachments?

This article shows that it makes sense to use heavy oil as the endotamponade of choice in the treatment of primary retinal detachment.

It is still often believed, incorrectly, that if it is necessary to use silicone oil, it should always be a light oil, and the only thing that may change is its density chosen by the doctor.

This logic should change.

Having proven products at our disposal, such as oils with a lower specific weight than water and heavy oils such as Densiron<sup>®</sup>, the choice of endotamponade should be dictated by the condition of the detached retina, the location of holes or tears, the presence of signs of vitreoretinopathy, etc.

Following this logic, in the case of huge tears, numerous holes in the retina located in the lower quadrants and in the case of a high risk that the retina will not "attach" after the use of gas endotamponade, heavy silicone oil should be the product of choice. The same applies to recurrent retinal detachments involving

the lower quadrants. If repair surgery is performed within a few or several days of the original procedure, a retinal laser therapy procedure in these quadrants and the administration of heavy silicone oil are often sufficient.

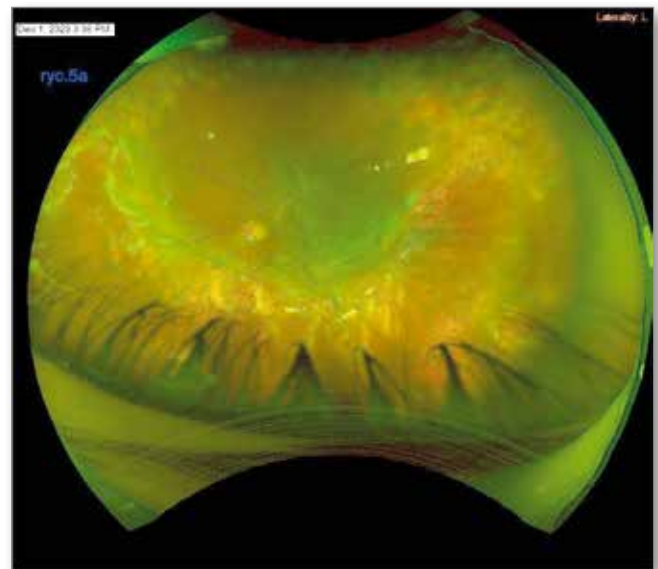
In cases where recurrent retinal detachment in lower quadrants lasts for a long time, even several weeks, even if it is necessary to perform peripheral retinotomy, there is a much greater chance that the retina will be permanently attached after using heavy silicone oil. It is worth adding that the most optimal postoperative position in the case of treatment of lower retinal detachments with heavy oil is sitting, standing and lying on the back, i.e. the positions we most often adopt during the day. In this way, the patient is able to maintain the correct postoperative position for most of the day.

Taking into account the presented results, two main conclusions can be drawn.

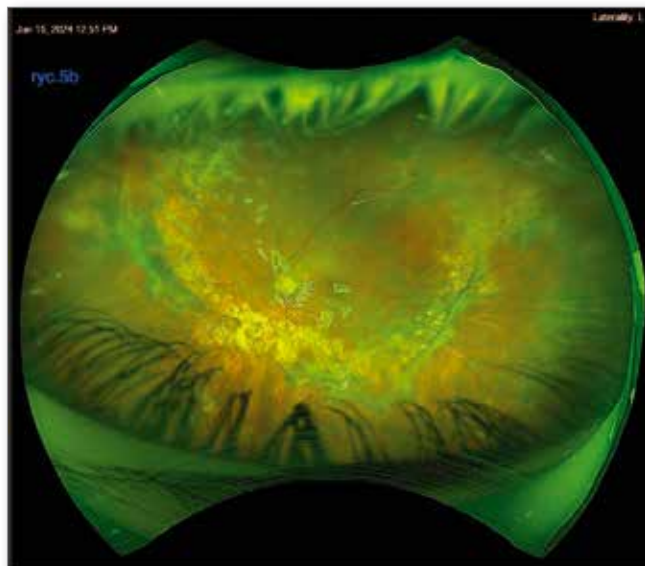
In the case of recurrent retinal detachments in lower quadrants, the most common procedure, which according to surgeons should give a favourable effect, was peripheral excision of the detached retina, in extreme, but not so rare cases, reaching the inferior arcades. Perhaps there was logic in this in the period before the introduction of heavy silicone oil, although even at that time, surgeons who tried to spare the retina and thus preserve the peripheral vision tended to perform indentation surgery at the site of detachment. Retinal excision in lower quadrants, mildly referred to by some as retinotomy rather than retinectomy, allows for the reattachment of the lower parts of the retina using light oil. However, this is a worse option for the patient because it involves partial, irreversible loss of the visual field (Fig. 5A, B).

Another issue is leaving the shrinking peripheral vitreous body, which seems to be the main cause of lower retinal detachments in a situation where the cause of primary retinal detachment was a tear in upper quadrants, which notably are protected from laser impacts and surrounded by the attached retina.

There is also no doubt that the effectiveness of permanent retinal attachment, both in primary and recurrent retinal detachment in lower quadrants, is higher when using heavy oil [3–5].



**Fig. 5A.** Wide-angle colour fundus photograph (OPTOS). A 32-year-old woman. Left eye. Condition before another repair procedure using heavy oil, after two attempts to attach the retina, with gas endotamponade (1 treatment), and administration of light oil and intraoperative retinal excision, reaching practically to the inferior arcades, performed in one of the "reference" centres. Visible retinal detachment and wrinkling affecting the posterior pole and upper quadrants. Visual acuity to far distances before the 1<sup>st</sup> posterior vitrectomy = 0.5 (Snellen) after the 2<sup>nd</sup> "repair" procedure = sense of movement. Complete, irreversible loss of peripheral vision.



**Fig. 5B.** Five weeks after retinal reattachment with Densiron® oil. The retina has been straightened out. It has been attached in places where it was detached. Visual acuity to far distances with best correction (+7.0 Dsph) improved to 0.8 logMAR.

## Conclusions

Heavy silicone oil should be used as the endotamponade of choice in the case of lower, primary and recurrent retinal detachments, when the cause of the detachment is in the lower quadrants and when the use of endotamponade with expansile gas or air is associated with a high risk of ineffectiveness. The peripheral vitreous that has not been removed appears to be the main cause of recurrent retinal detachment. The transient postoperative increase in intraocular pressure normalizes with the use of drugs that lower eye pressure.

## Disclosure

Conflict of interests: none declared

Funding: no external funding

Ethics approval: Not applicable.

## References:

1. <https://www.fluoron.de/products/long-term-tamponades/densiron-xtra/?lang=en>
2. Cornacel C, Dumitrescu OM, Zaharia AC, et al.: *Surgical Treatment in Silicone Oil-Associated Glaucoma*. Diagnostics (Basel). 2022 Apr 16; 12(4): 1005. doi: 10.3390/diagnostics12041005. PMID: 35454053; PMCID: PMC9031548.
3. Auriol S, Pagot-Mathis V, Mahieu L, et al.: *Efficacy and safety of heavy silicone oil Densiron 68 in the treatment of complicated retinal detachment with large inferior retinectomy*. Graefes Arch Clin Exp Ophthalmol. 2008 Oct; 246(10): 1383–1389. doi: 10.1007/s00417-008-0876-6. Epub 2008 Jun 28. PMID: 18587596.
4. Caporossi T, Franco F, Finocchio L, et al.: *Densiron 68 heavy silicone oil in the management of inferior retinal detachment recurrence: analysis on functional and anatomical outcomes and complications*. Int J Ophthalmol. 2019 Apr 18; 12(4): 615–620. doi: 10.18240/ijo.2019.04.15. PMID: 31024816; PMCID: PMC6469568.
5. Romano MR, Stappler T, Marticorena J, et al.: *Primary vitrectomy with Densiron-68 for rhegmatogenous retinal detachment*. Graefes Arch Clin Exp Ophthalmol. 2008 Nov; 246(11): 1541–1546. doi: 10.1007/s00417-008-0894-4. Epub 2008 Jul 11. PMID: 18618126.
6. Moussa G, Tadros M, Ch'ng SW, et al.: *Outcomes of Heavy Silicone Oil (Densiron) compared to Silicone Oil in primary rhegmatogenous retinal detachment: a multivariable regression model*. Int J Retin Vitre. 2022; 8: 61. <https://doi.org/10.1186/s40942-022-00413-0>
7. Li W, Zheng J, Zheng Q, et al.: *Clinical complications of Densiron 68 intraocular tamponade for complicated retinal detachment*. Eye. 2010; 24: 21–28. <https://doi.org/10.1038/eye.2009.57>

## Contact and reprint request:

Adam Cywiński, MD (e-mail: [adam.cywinski@solcho.pl](mailto:adam.cywinski@solcho.pl))

Śląskie Centrum Leczenia Oczu w Żorach

ul. Okrężna 11, 44-240 Żory