

Refractory Central Serous Retinal Detachment in the Presence of Optic Disc Pit – Case Report

Radosław Kaczmarek¹, Dorota Kaczmarek²

¹ Department of Ophthalmology, Medical University of Wrocław, Poland

Head: Professor Marta Misiuk-Hojto, MD, PhD

² Ophthalmology Clinical Centre SPEKTRUM, Wrocław, Poland

Summary:

Among congenital optic disc anomalies are megalopapilla, optic nerve aplasia and hypoplasia (de Morsier's syndrome) and optic disc excavations. The latter are attributed to abnormal fetal fissure's closure. There is a wide spectrum of these anomalies ranging from single optic disc pit, to multiple pits, to morning glory syndrome. Excavated defects of the optic disc are usually associated with retinal detachment in the macular region. It is usually confined to the macular region though a subtotal or total retinal detachment may occur. It requires treatment (a surgical approach in most cases) though a spontaneous resolution of the subretinal fluid within a short period of the detachment onset has been observed. We report a case of unilateral central serous retinal detachment in the presence of a bilateral optic disc pit refractory to primary treatment.

Key words:

optic disc pit, central serous retinal detachment, pars plana vitrectomy (PPV).

Introduction

Optic nerve pit is a congenital, mostly unilateral ocular disorder. It was first described by Wieth in 1882. Its prevalence is 1:10 000 and it is rarely hereditary and bilateral in 10-15% of cases. It may be associated with a visual field defect which often does not correspond with the pit's localization – usually an arcuate central scotoma connected with the blind spot [1–3].

The optic nerve pit is mostly localized on the temporal disc margin: 72% of the cases. 21% of cases localize centrally, 5% on the inferior, and 2% on the nasal disc margin [4].

Among complications the most common are chorionovascularization (CNV), macular edema and serous retinal detachment with retinoschisis of the neurosensory retina in the macular region (optic disc pit maculopathy, ODPM). The latter appears in about 30–75% of cases (Kranenburg's syndrome).

Sobol et al. observed 15 patients with optic nerve pit and ODPM for a closed period of 21 years (mean time 9 years). A drop in visual acuity (VA) to 0.1 on the Snellen chart or below was observed in 12 cases. Mean time of the visual impairment was 6 months after retinal detachment diagnosis [5].

Brown et al. observed 75 patients with optic nerve pit. Twenty patients (52%) developed central serous retinal detachment. Five-year follow-up revealed mean visual acuity of 20/80 [4].

It is not clear what the exact pathomechanism of the subretinal fluid accumulation is. Among many theories are leakage of the retinal vessels located within the pit area, direct choroidal leakage at the peripapillary atrophy area, cerebrospinal fluid leakage from the subarachnoid space, and intraocular fluid through the pit [6, 7].

Material and methods

We present a case of 31-year-old woman with bilateral optic nerve pit and worsening of visual acuity (VA) in the left eye.

Results

The patient was admitted to our hospital to the A & E Ward in July 2007 with a suddenly noticed drop of her left eye VA. At the time the best corrected visual acuity (BCVA) was: right eye (RE) 1.0 and 0.7 left eye (LE) on the Snellen chart. She was diagnosed with bilateral optic nerve pit (Fig. 1). The initial decision was observation

but when after 1 month her BCVA dropped to 0.125 LE and the central retinal thickness (CRT) was 723 μ m due to the accumulated fluid (ODPM) (Fig. 2), 23G pars plana vitrectomy (PPV) with internal limiting membrane (ILM) peeling and gas endotamponade (12% C3F8) was performed. Best corrected visual acuity at 1 month follow-up was 0.9, central retinal thickness (CRT) was 290 μ m. The post-operative treatment regime was Tobradex (tobramycin/ dexamethasone) 6 times a day tapered gradually and 1% tropicamide once a day discarded after three weeks. Visual acuity was stable until February, 2014. When BCVA LE suddenly dropped to 0.6, near visual acuity to D-1.0, the Amsler test was positive and there was an increase in CRT to 576 μ m (while the highest retinal elevation point was 858 μ m just temporal to the disc margin), in March, 2014 the 23G pars plana vitrectomy (PPV) with laser photocoagulation along the optic disc margin and gas endotamponade (12% C3F8) was performed. Just prior to the surgery the CRT was 893 μ m. Best corrected visual acuity at 1 month follow-up was 0.5 and there was an increase of the intraocular pressure to 37 mmHg. The post-operative treatment regime, initially the same as after the first surgery, was changed to diclofenac sodium 5 times a day LE and 0.5% timolol b.i.d. LE was added. The intraocular pressure (IOP) reacted well to treatment

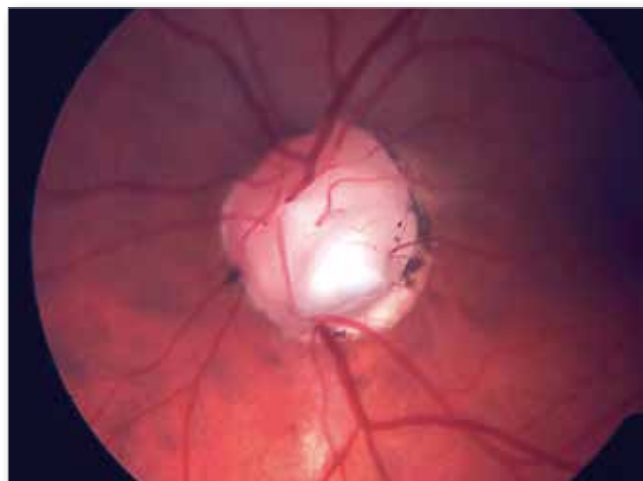


Fig. 1. Fundus photography (LE) – optic disc pit.

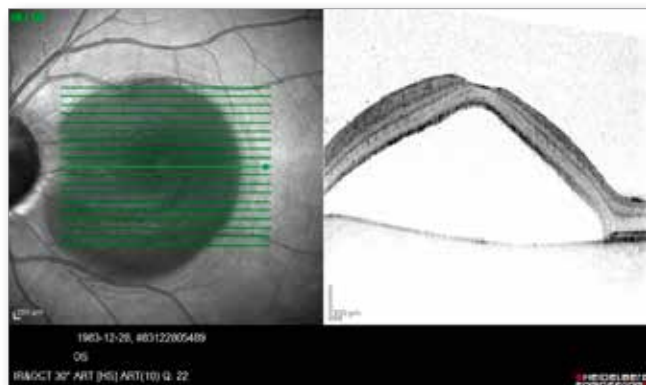


Fig. 2. Optical coherence tomography (LE) in advanced stage of disease.

and we were able to discard timolol after approximately 6 weeks, by which time the C3F8 was totally absorbed. By May, 2014 BCVA LE dropped to 0.08 and CRT was 1123 μm – hence the patient was once again scheduled for PPV. But on the day of admission to the hospital we noticed a sudden VA and CRT improvement – BCVA was 0.6, Sn D-0.5 (though the Amsler test was still positive), CRT 236 μm – and we decided to put the surgical treatment on hold and observe instead. Once again the situation was stable for some time – we did not notice any significant changes in either VA or in CRT until December, 2015, when the BCVA dropped to 0.2 LE, CRT was 986 μm and in January 2016 25G PPV with the pit “plug” using internal limiting membrane and gas endotamponade (12% C3F8) was performed. At 2 months follow-up the VA left eye was 0.6 and once again there was an increase of the IOP to 34 mmHg. In optical coherence tomography (OCT) we still observed a residual submacular fluid. Acetazolamide t.i.d. and potassium supplements q.d. were added. BCVA at 3 months follow-up was 0.8, CRT 360 μm . In the next 2 months we observed regression of subretinal fluid and a drop in central retinal thickness in OCT (172 μm).

Best corrected visual acuity LE at the last follow-up visit (July, 2019) was 0.9, IOP 18 mmHg (Fig. 3). Best corrected visual acuity of the RE did not change throughout the whole observation period and was 1.0 on the Snellen chart.

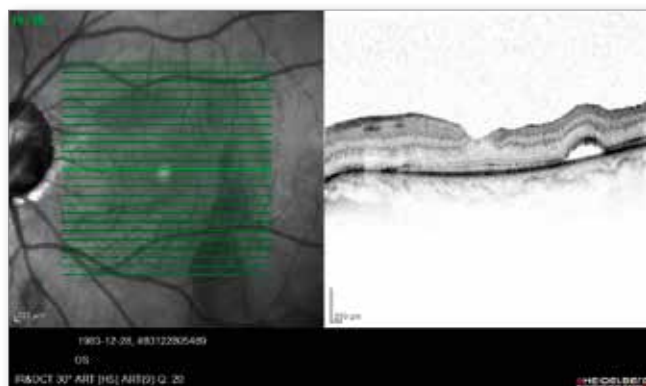


Fig. 3. Optical coherence tomography (LE) at end of treatment.

Discussion

As of yet there are no definite guidelines considering treatment. Methods such as systemic corticosteroids, optic nerve sheath relaxation and cerclage did not prove beneficial. Among many options are laser treatment along the temporal disc margin (which is meant to produce a barrier of chorioretinal adhesions at the optic disc border) [6], gas endotamponade (which is supposed to enable pushing away the subretinal fluid), PPV with or without ILM peeling (the peeling is supposed to exclude the tangential retinovitreous tractional mechanism) and more recent introduction of the pit “plug” using internal limiting membrane,

platelets, fibrin glue, neurosensory retinal transplant and autologous scleral graft.

Akiyama et al. in a paper published in 2013 presented the results of a gas endotamponade alone. In 4 out of 8 eyes the retinal detachment resolved completely with mean gas injections 1.8. The follow-up time was 5 to 11 years [8]. A similar method was described by Lincoff and Kreissig in 1998 [9].

Carlos Augusto Moreira Neto and Carlos Augusto Moreira Junior published a long-term evaluation of vitrectomy and gas-fluid exchange, with no laser treatment, in serous macular detachment due to optic disc pit. They evaluated 5 patients who were followed for 13.7 years approximately, post-operatively resulting in improvement of visual acuity, redetachment of the central retina and no need for further treatment [10].

Laser treatment along the temporal disc margin was described by Gass in 1969 [6]. This method alone is often not successful and requires repeated procedures.

It must be made clear that the above described methods are not free from complications, no matter how high their published rate of success is. In cases with intraocular tamponade there were reports of subretinal migration of either gas or silicone oil, either intraoperatively or postoperatively. Photocoagulation at the temporal disc margin might mean destroying nerve fibers in the papillomacular bundle, which results in scotoma in the central visual field.

As shown above, none of these methods is clearly preferable to others, and the choice of treatment depends mostly on available options and the surgeon's own preferences.

Disclosure

Conflict of interests: none declared

Funding: no external funding

Ethics approval: Not applicable.

References:

1. Grear JN Jr.: Pits, or crater-like holes in the optic disc. *Ach Ophthalmology*. 1942; 28: 467–483.
2. Dithmar S, Schuett F, Voelcker HE, et al.: Delayed sequential occurrence of perfluorodecalin and silicone oil in the subretinal space following retinal detachment surgery in the presence of an optic disc pit. *Arch Ophthalmol*. 2004 Mar; 122(3): 409–411.
3. Becht C, Senn P, Lange AP: Delayed occurrence of subretinal silicone oil after retinal detachment surgery in an optic disc pit – a case report. *Klin Monbl Augenheilkd*. 2009 Apr; 226(4): 357–358. doi: 10.1055/s-0028-1109249. Epub 2009 Apr 21.
4. Brow GC, Shields JA, Goldberg RE: Congenital pits of the optic nerve head. II. Clinical studies in humans *Ophthalmology* 1980; 87: 51–65.
5. Aobol WM, Boldi CF, Folk JC, et al.: Long term visual outcome in patients with optic nerve pit and serous retinal detachment of the macula. *Ophthalmology*. 1990; 79: 1539–1542.
6. Gass JDM: Serous detachment of the macula secondary to congenital pit of the optic nerve head. *Am J Ophthalmol*. 1969; 67: 821–841.
7. Lincoff H, Schiff W, Krivoy D, et al.: Optic coherence tomography of optic disc pit maculopathy. *Am J Ophthalmol*. 1996; 122: 264–266.
8. Akiyama H, Shimoda Y, Fukuchi M: Intravitreal gas injection without vitrectomy for macular detachment associated with an optic disc pit. *Retina*. 2013; 0: 1–6.
9. Lincoff H, Kreissig I: Optical coherence tomography of pneumatic displacement of optic disc pit maculopathy. *Br J Ophthalmol*. 1998; 82: 367–372.
10. Carlos AMN, Carlos AMJ: Vitrectomy and gas-fluid exchange for the treatment of serous macular detachment due to optic disc pit: long term evaluation. *Arq Bras Ophthalmol*. (Sao Paulo) 2013 May/June; Vol. 76: no. 3.

Contact and reprint request:

Radosław Kaczmarek, MD, PhD (e-mail: radoslaw.kaczmarek@umw.edu.pl)

Katedra i Klinika Okulistyki Uniwersytetu Medycznego we Wrocławiu

ul. Borowska 213, 50-556 Wrocław