

# Long-term Complications and Treatment after Excision of Periocular Basal Cell Carcinoma – Case Report

Michalina Gatuszka, Dorota Pojda-Wilczek

Department of Ophthalmology, Faculty of Medical Sciences in Katowice, Medical University of Silesia in Katowice, Poland  
Head: Professor Dorota Wyględowska-Promieńska, MD, PhD

## Abstract:

**Introduction:** Basal cell carcinoma is the most common malignant skin tumor, accounting for 90% of cases. The most important risk factors include age, male sex, skin phototypes I and II, frequent exposure to the sun, sunburn and positive family history of other skin tumors. More than 75% of basal cell carcinomas occur in the head and neck region. About 20% appear in the periocular region.

**Case report:** A 76-year-old male patient was referred to the Ophthalmology Clinic due to keratopathy of the right eye as a result of postoperative eyelid regurgitation. Eleven years earlier, the patient had undergone surgical excision of basal cell carcinoma in the right temporal region, which resulted in eyelid regurgitation. Anterior segment examination of the right eye revealed symblepharon, eyelid regurgitation, limited mobility and keratopathy. The patient underwent surgery, during which symblepharon lysis, reconstruction of the conjunctival sac with a lower lip mucosa free graft and upper eyelid plasty with a skin graft from the right eyelid were performed. There were no postoperative complications. The mucosal graft healed properly and the patient was able to close his right eyelids. The patient was closely monitored in the clinic for 8 years after the procedure; the local condition of the right eye remained stable.

**Conclusions:** Reconstruction of the eyelids and ocular surface using lip mucosal and skin grafts provides an effective method of eyelid regurgitation and symblepharon treatment, preserving the function of the eyelids and protecting the ocular surface.

## Key words:

basal cell carcinoma, BCC, blepharoplasty, keratopathy, symblepharon.

## Introduction

The occurrence of all skin malignancies is increasing worldwide. The incidence of periocular skin tumors depends on geographical area and racial group. Basal cell carcinoma (BCC) is the most common malignant skin tumor, accounting for 90% of cases [1]. The incidence is higher in age over 60. High exposure to ultraviolet radiation is one of the most known risk factors [2]. Other important risk factors are age, male sex, skin phototype I and II, frequent sun exposure and sunburn, and positive family history of other skin tumors [3–8].

Over 75% of BCCs occur in the head and neck region. About 20% of BCCs appear in the periocular region [9, 10]. Any periocular skin malignancy can invade the orbit and raise the probability of further complications leading to exenteration. Orbital invasion is rather uncommon, with a reported incidence about 2% to 4% [11]. Invasion risk factors include multiple recurrences, large size of the primary tumor, infiltrative histological subtype, the medial canthus or inner angle localization and age over 70 [1, 2]. More than 50% of BCCs occur on the lower eyelid and inner angle, 30% on the medial canthus, 15% on the upper eyelid and 5% on the lateral canthus [10].

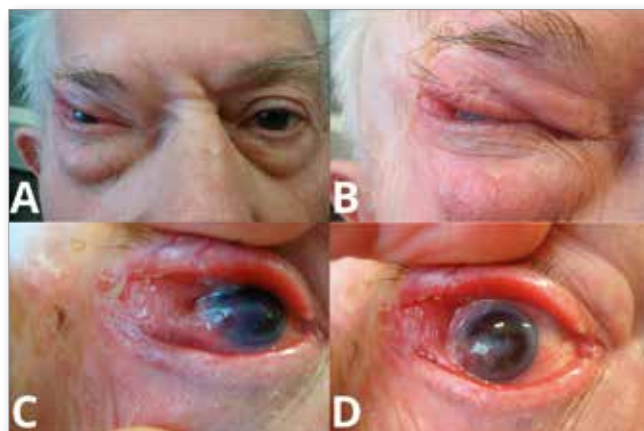
BCC is often characterized by pink color, but in advanced stages there can be ulceration and bleeding, a visible or palpable mass leading to limitation of ocular motility, immobile eyelids or ptosis [10, 12].

Surgical excision is the main treatment of BCC. Margin control is necessary to reduce the risk of local recurrence. Depending on the stage, localization and pathological variety of the BCC a cure rate of about 95% is achieved after treatment [13–15]. The risk of recurrence after surgery is estimated at 5–15%. The rate of recurrence depends on the localization, size, infiltration and histological type. The most recurrences appear on the lower eyelid, in the medial canthus and in infiltrative types. Aggressive histological forms of BCC are also associated with a higher risk of recurrence [16–18].

## Case presentation

A 76-year-old male patient was referred to the Ophthalmology Clinic due to keratopathy in his right eye as a result of postoperative regurgitation of the eyelids. Eleven years earlier, the patient had undergone surgical excision of basal cell carcinoma in the right temporal area, which resulted in eyelid regurgitation. Moreover, the patient was treated for glaucoma in both eyes; full local treatment was used. He was in good general condition, without any general diseases.

At the initial examination, the best corrected visual acuity (BCVA) of the right eye was 0.4, the left eye – hand motion. The intraocular pressure (IOP) in the right eye was normal, while in the left eye it was 34 mmHg. Anterior segment examination of the right eye revealed symblepharon, eyelid regurgitation, limited mobility, keratopathy, cataract, pseudoexfoliation syndrome (PEX) and posterior synechiae (Fig. 1). Fundus examination was impossible to perform.



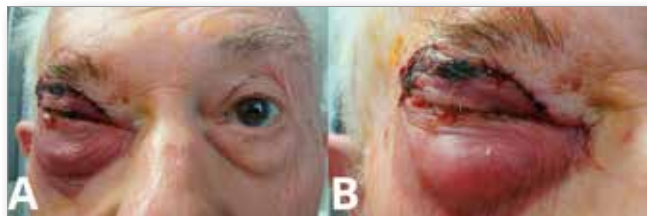
**Fig. 1.** Initial examination: A, B – right eyelid regurgitation after periocular BCC excision, C – symblepharon, D – keratopathy, central corneal haze.

The left eye examination showed cataract, PEX, posterior synechiae and glaucomatous optic neuropathy.

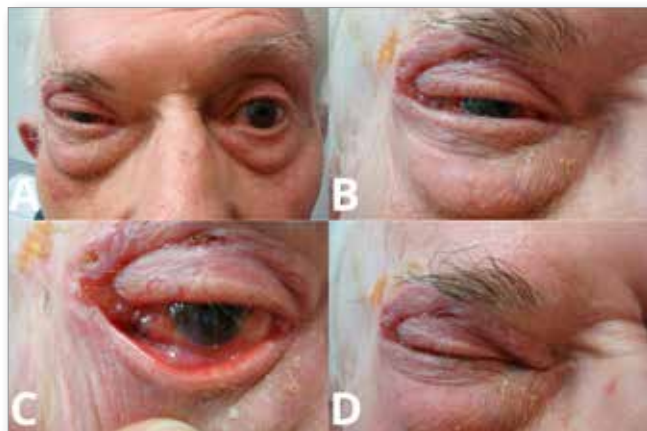
Due to increased intraocular pressure, the patient was urgently referred for antiglaucoma surgery in the left eye. Diode laser cyclophotocoagulation was performed, achieving normalization and stabilization of intraocular pressure.

Because of the suspicion of recurrence of basal cell carcinoma in the right periocular region, the patient was also urgently referred for magnetic resonance imaging examination (MRI) for diagnostics before possible reoperation. The examination did not reveal any signs of cancerous infiltration – the patient was referred for blepharoplasty.

Three months later, the patient was admitted to the Ophthalmological Department to undergo the surgery. In the admission examination: BCVA of the right eye was 0.3, BCVA of the left eye – hand motion. IOP in both eyes was 13 mmHg. The eye surgeon performed symblepharon lysis, reconstruction of the conjunctival sac with a lower lip mucosa free graft and upper eyelid plasty with a skin graft from the right eyelid. The procedure was performed without complications. The patient was discharged in good general and local condition; BCVA of the right eye was 0.4 after surgery. The mucosal graft healed properly and the patient was able to close his right eyelids (Fig. 2, 3).



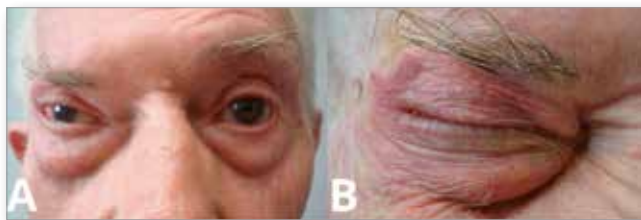
**Fig. 2.** A, B – one day after eyelid reconstruction.



**Fig. 3.** A, B, C, D – seven days after eyelid reconstruction.

Taking into account the patient's monocularity, cataract surgery in the right eye was considered as the next step of treatment. Six months later, the patient was admitted to the hospital for cataract surgery in his right eye, but was disqualified because of keratitis – microfilaments, corneal epithelial defects, central corneal haze and neovascularization. The patient was prescribed anti-inflammatory treatment.

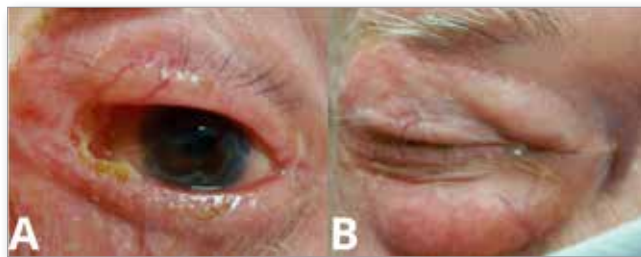
When the inflammation resolved and the cornea condition normalized, despite the indications for cataract surgery, the patient was disqualified from the procedure twice again. It was because of the high risk of cornea decompensation of the only seeing eye that allowed independent functioning. There were also no indications for re-blepharoplasty. The patient was examined regularly and his condition was stable (Fig. 4).



**Fig. 4.** A, B – one year after eyelid reconstruction.

After seven years, the BCVA of the right eye deteriorated to 0.05, BCVA of the left eye – sense of light. The patient's visual acuity made it practically impossible to function independently. A decision was made to reschedule the patient for cataract surgery with artificial intraocular lens implantation. Two months later, the procedure was performed successfully without any complications. Visual acuity of the right eye 0.3–0.4 was achieved.

The patient was followed up in our clinic for a year after the procedure; the local condition of the right eye remained stable (Fig. 5).



**Fig. 5.** A, B – seven years after eyelid reconstruction.

## Discussion

This case report indicates that eyelid reconstruction using a combination of lip mucosal graft and eyelid skin graft represents an efficient technique for the treatment of eyelid regurgitation and symblepharon after periocular basal cell carcinoma excision.

The integrity of the eyelids and its function is important for protecting and preserving the function of the eye surface. Reconstruction with a skin flap is necessary to preserve eyelid function and obtain a good cosmetic result. A skin flap is only one of many different factors and techniques that eyelid reconstruction entails, and oversimplifies the process of reconstruction. The localization of the tumor on the eyelid margin makes surgical reconstruction more difficult. The smaller the size of the tumor is, the simpler the surgical reconstruction and better the functional and cosmetic results can be [14].

Conventional management of symptomatic symblepharon varies from frequent ocular lubrication using artificial tears and ointment to occlusion of the tear drainage duct and others. Surgical intervention involves symblepharon lysis, mucosal grafts, conjunctival autografts, or amniotic membrane transplantation. Mucosal grafts are easily harvested without substantial scarring, and mucous membrane from the lip contains goblet cells that may stabilize the tear film by contributing mucin in the eye [19].

Orbital invasion may often be clinically silent; physicians need to be alert to the possibility in high-risk tumors and consider appropriate imaging. MRI should be used for visualizing soft tissues changes.

In the case of keratopathy, when performing other ophthalmological procedures is necessary, the risk of complications is much higher; therefore the patient requires appropriate assessment of eligibility for the procedure, a stable local condition and no signs of inflammation. Otherwise, there is a risk of corneal decompensation, deterioration of visual acuity and even need for a corneal

transplantation. In the case of our patient, there was no corneal decompensation after cataract surgery. Incomplete visual acuity after the procedure was not due to complications in the anterior segment of the eye, but to advanced glaucoma. Several stages of treatment of the only seeing eye enabled the patient to live independently and improved his quality of life for several years.

## Conclusions

Reconstruction of the eyelids and ocular surface using lip mucosal and skin grafts provided an effective approach to the treatment of eyelid regurgitation, even many years after its development. Removal of tumors localized around the eye should be combined with precise reconstruction of the eyelids' anatomy and protection of the eye surface against the effects of regurgitation.

## Disclosure

Conflict of interests: none declared

Funding: no external funding

Ethics approval: Not applicable.

## References:

1. Furdova A, Lukacko P: *Periocular Basal Cell Carcinoma Predictors for Recurrence and Infiltration of the Orbit*. J Craniofac Surg. 2017 Jan; 28(1): e84–e87. doi: 10.1097/SCS.0000000000003242. PMID: 27906855; PMCID: PMC5266411.
2. Furdova A, Kapitanova K, Kollarova A, et al.: *Periocular basal cell carcinoma – clinical perspectives*. Oncol Rev. 2020 Apr 30; 14(1): 420. doi: 10.4081/oncol.2020.420. PMID: 32395200; PMCID: PMC7204832.
2. van Iersel CA, van de Velden HVN, Kusters CDJ, et al.: *Prognostic factors for a subsequent basal cell carcinoma: implications for follow-up*. Br J Dermatol. 2005; 153: 1078–1080.
4. Levi F, Randimbison L, Maspoli M, et al.: *High incidence of second basal cell skin cancers*. Int J Cancer 2006; 119: 1505–1507.
5. Ramachandran S, Fryer AA, Lovatt TJ, et al.: *Combined effects of gender, skin type and polymorphic genes on clinical phenotype: use of rate of increase in numbers of basal cell carcinomas as a model system*. Cancer Lett. 2003; 189: 175–181.
6. Karagas MR, Stukel TA, Greenberg ER, et al.: *Risk of subsequent basal cell carcinoma and squamous cell carcinoma of the skin among patients with prior skin cancer*. Skin Cancer Prevention Study Group. JAMA. 1992; 267: 3305–3310.
7. Lear JT, Tan BB, Smith AG, et al.: *Risk factors for basal cell carcinoma in the UK: case-control study in 806 patients*. J R Soc Med. 1997; 90: 371–374.
8. Wallberg P, Kaaman T, Lindberg M: *Multiple basal cell carcinoma. A clinical evaluation of risk factors*. Acta Derm Venereol. 1998; 78: 127–129.
9. Saleh GM, Desai P, Collin JRO, et al.: *Incidence of eyelid basal cell carcinoma in England: 2000-2010*. Br J Ophthalmol. 2017; 101: 209–212.
10. Sun MT, Wu A, Figueira E, et al.: *Management of periocular basal cell carcinoma with orbital invasion*. Future Oncol Lond Engl. 2015; 11: 3003–3010.
11. Madge SN, Khine AA, Thaller VT, et al.: *Globe-sparing surgery for medial canthal Basal cell carcinoma with anterior orbital invasion*. Ophthalmology. 2010; 117: 2222–2228.
12. Leibovitch I, McNab A, Sullivan T, et al.: *Orbital invasion by periocular basal cell carcinoma*. Ophthalmology. 2005; 112: 717–723.
13. Sun MT, Wu A, Huilgol SC, et al.: *Accuracy of Biopsy in Subtyping Periocular Basal Cell Carcinoma*. Ophthal Plast Reconstr Surg, 2015; 31: 449–451.
14. Newlands C, Currie R, Memon A, et al.: *Non-melanoma skin cancer: United Kingdom National Multidisciplinary Guidelines*. J Laryngol Otol. 2016; 130: S125–132.
15. Shi Y, Jia R, Fan X: *Ocular basal cell carcinoma: a brief literature review of clinical diagnosis and treatment*. OncoTargets Ther. 2017; 10: 2483–2489.
16. Furdová A, Horkovicová K, Babál P, et al.: *Non-melanotic Tumors of the Eyelids Skin and Inner Corner - Basocellular Carcinoma*. Ceska Slov Oftalmol Cas/ Ceske Oftalmol Spolecnosti Slov Oftalmol Spolecnosti. 2015; 71: 293–301.
17. Ho SF, Brown L, Bamford M, et al.: *5 Years review of periocular basal cell carcinoma and proposed follow-up protocol*. Eye. 2013; 27: 78–83.
18. Honavar SG, Manjandavida FP: *Tumors of the ocular surface: A review*. Indian J Ophthalmol 2015; 63: 187–203.
19. Iyer G, Pillai VS, Srinivasan B, et al.: *Mucous membrane grafting for lid margin keratinization in Stevens-Johnson syndrome: results*. Cornea. 2010; 29: 146–151.

## Contact and reprint request:

Michalina Gałuszka, MD (e-mail: [michalina.galuszka@gmail.com](mailto:michalina.galuszka@gmail.com))  
Department of Ophthalmology, Faculty of Medical Sciences in Katowice,  
Medical University of Silesia in Katowice  
35 Ceglana, 40-514 Katowice, Poland